

PEDIATRIC EMERGENCY MEDICINE PRACTICE

AN EVIDENCE-BASED APPROACH TO PEDIATRIC EMERGENCY MEDICINE ▲ EBMEDICINE.NET

Childhood Rashes That Present To The ED Part I: Viral And Bacterial Issues

You're managing to keep your head above water during the evening shift in the pediatric emergency department of a university hospital when you get a phone call from a local physician who's sending you a dilemma that she's been struggling with for three days. The case is a four-year-old girl who recently moved from Russia (unknown vaccination status) with persistent fever over 40°C for three days. The child is "toxic" appearing and has impressive coryza and a non-productive cough. Her eyes are very red with scant non-purulent discharge for which the pediatrician prescribed antibiotic drops. The child developed a rather impressive non-pruritic facial rash that rapidly spread to the trunk. Despite a negative "rapid strep" test and blood and urine cultures, the pediatrician's concern for this "toxic" kid was sufficiently worrisome that she elected to start antibiotics. In the pediatric ED, the child is noted to be normotensive, but is tachycardic (consistent with her febrile state). The exam confirmed the report by the pediatrician and found non-exudative pharyngitis and pustules on the buccal mucosa opposite the molars. A serologic test was sent that confirmed the suspicion of the attending on duty.

Pediatric dermatology often poses a challenge to practitioners of emergency medicine. When making dermatologic diagnoses, it is important to examine the skin carefully, paying special attention to distribution and morphology of lesions, as well as hair, nail, and mucosal changes.

Common cutaneous disorders may present differently in African American patients; when compared with caucasians, the lesions of atopic dermatitis in African Americans often occur on the extensor rather than flexor surfaces, are grey rather than erythematous, and are more elevated in appearance. Hypo and hyperpig-

March 2007
Volume 4, Number 3

Author

Marc S. Lampell, MD

University of Rochester School of Medicine and Dentistry, Assistant Professor of Emergency Medicine, Assistant Professor of Pediatrics

Peer Reviewers

Sharon Mace, MD

Associate Professor, Emergency Department, Ohio State University School of Medicine, Director of Pediatric Education And Quality Improvement and Director of Observation Unit, Cleveland Clinic, Faculty, MetroHealth Medical Center, Emergency Medicine Residency

Paula J. Whiteman, MD

Medical Director, Pediatric Emergency Medicine, Encino-Tarzana Regional Medical Center; Attending Physician, Cedars-Sinai Medical Center, Los Angeles, CA

CME Objectives

Upon completing this article you should be able to:

1. Recognize the different potencies of topical steroids.
2. Review diagnostic techniques germane to dermatology.
3. Develop a differential diagnosis and management plan for rashes which are a manifestation of infection viral, bacterial, fungal, parasitic, or idiopathic.

Date of original release: March 1, 2007.

Date of most recent review: February 1, 2007.

See "Physician CME Information" on back page.

All figures in this article are available to paid subscribers in color at www.ebmedicine.net under "Topics".

Editorial Board

Jeffrey R. Avner, MD, FAAP, Professor of Clinical Pediatrics, Albert Einstein College of Medicine; Director, Pediatric Emergency Service, Children's Hospital at Montefiore, Bronx, NY.

T. Kent Denmark, MD, FAAP, FACEP, Residency Director, Pediatric Emergency Medicine; Assistant Professor of Emergency Medicine and Pediatrics, Loma Linda University Medical Center and Children's Hospital, Loma Linda, CA.

Michael J. Gerardi, MD, FAAP, FACEP, Clinical Assistant Professor, Medicine, University of Medicine and Dentistry of New Jersey; Director, Pediatric Emergency Medicine, Children's Medical Center, Atlantic Health System; Department of Emergency

Medicine, Morristown Memorial Hospital.

Ran D. Goldman, MD, Associate Professor, Department of Pediatrics, University of Toronto; Division of Pediatric Emergency Medicine and Clinical Pharmacology and Toxicology, The Hospital for Sick Children, Toronto.

Martin I. Herman, MD, FAAP, FACEP, Professor of Pediatrics, Division Critical Care and Emergency Services, UT Health Sciences, School of Medicine; Assistant Director Emergency Services, Lebonheur Children's Medical Center, Memphis TN.

Mark A. Hostettler, MD, MPH, Assistant Professor, Department of Pediatrics; Chief, Section of Emergency Medicine; Medical Director, Pediatric Emergency Department, The University of

Chicago, Pritzker School of Medicine, Chicago, IL.

Alson S. Inaba, MD, FAAP, PALS-NF, Pediatric Emergency Medicine Attending Physician, Kapiolani Medical Center for Women & Children; Associate Professor of Pediatrics, University of Hawaii John A. Burns School of Medicine, Honolulu, HI; Pediatric Advanced Life Support National Faculty Representative, American Heart Association, Hawaii & Pacific Island Region.

Andy Jagoda, MD, FACEP, Vice-Chair of Academic Affairs, Department of Emergency Medicine; Residency Program Director; Director, International Studies Program, Mount Sinai School of Medicine, New York, NY.

Tommy Y Kim, MD, FAAP, Attending Physician, Pediatric Emergency

Department; Assistant Professor of Emergency Medicine and Pediatrics, Loma Linda Medical Center and Children's Hospital, Loma Linda, CA.

Brent R. King, MD, FACEP, FAAP, FAAEM, Professor of Emergency Medicine and Pediatrics; Chairman, Department of Emergency Medicine, The University of Texas Houston Medical School, Houston, TX.

Robert Luten, MD, Professor, Pediatrics and Emergency Medicine, University of Florida, Jacksonville, Jacksonville, FL.

Ghazala Q. Sharieff, MD, FAAP, FACEP, FAAEM, Associate Clinical Professor, Children's Hospital and Health Center/ University of California, San Diego; Director of Pediatric Emergency Medicine, California Emergency Physicians.

Gary R. Strange, MD, MA, FACEP, Professor and Head, Department of Emergency Medicine, University of Illinois, Chicago, IL.

Adam Vella, MD, Assistant Professor of Emergency Medicine, Pediatric EM Fellowship Director, Mount Sinai School of Medicine, New York

Mike Witt, MD, MPH, Attending Physician, Division of Emergency Medicine, Children's Hospital Boston; Instructor of Pediatrics, Harvard Medical School

Research Editor

Christopher Strother, MD, Fellow, Pediatric Emergency Medicine, Mt. Sinai School of Medicine, Chair, AAP Section on Residents

Commercial Support: *Pediatric Emergency Medicine Practice* does not accept any commercial support. All faculty participating in this activity report no significant financial interest or other relationship with the manufacturer(s) of any commercial product(s) discussed in this educational presentation.

mentation are seen frequently in African American patients with atopic dermatitis.¹⁻⁹ Another dermatosis that often has a unique clinical presentation in African Americans is pityriasis rosea where the lesions may be distributed in an “inverse” pattern, with the extremities and face being more involved than the trunk.⁷⁻⁹

This article discusses specific common dermatologic entities within the broad categories of infectious disease, eczematous disorders, inflammatory disease, and neoplastic disease.

Epidemiology

The frequency of skin complaints is fairly constant despite the season of the year. Skin complaints amount to almost a quarter of outpatient visits.

As depicted in the table below, five general dermatologic categories accounted for 81.5% of the pri-

Table 1. A Study By Dr. Tunnessen From The Pediatric Outpatient Clinic At Upstate Medical Center In Syracuse, New York

| Diagnosis | Percentage of Disorder |
|------------------------------------|------------------------|
| Bacterial Skin Infections | 17.5 |
| Impetigo | 10 |
| Cellulitis | 6 |
| Folliculitis | 1.5 |
| Viral Skin Infections | 6.5 |
| Exanthem | 4 |
| Warts | 2 |
| Molluscum | 0.5 |
| Fungal Skin Infections | 14.5 |
| Tinea Corporis | 3 |
| Tinea Capitis | 7 |
| Monilia | 4.5 |
| Parasitic Skin Infestations | 5.5 |
| Pediculosis | 2 |
| Flea bites | 2 |
| Scabies | 1.5 |
| Dermatitis | |
| Atopic Dermatitis | 14.5 |
| Diaper Dermatitis | 11 |
| Contact Dermatitis | 8.5 |
| Seborrheic Dermatitis | 3.5 |

Table 1b. A Study By Dr. Tunnessen From The Pediatric Outpatient Clinic At Upstate Medical Center In Syracuse, New York

| Month | Percentage of children presenting with skin complaints |
|-----------|--|
| August | 21.4 |
| September | 21.8 |
| October | 24.4 |
| December | 30.2 |
| January | 23.2 |
| Total | 24 |

mary care visits. The most frequent were infections (38.5%); fungal infections accounted for almost 15% of all complaints.

Diagnostic Tests

In making dermatologic diagnoses, certain techniques can be useful in confirming clinical suspicion. One of the most basic techniques used is the potassium hydroxide (KOH) preparation for the diagnosis of dematophytosis. For this technique, use a number 15 blade to scrape the skin from the outer border of a suspected tinea infection onto a glass slide. Then, place two drops of 10% KOH over the scale and heat over a flame for 15 to 30 seconds to fix the preparation. A survey of the slide under low power will reveal suspected hyphae.^{8,9,15} In the case of an equivocal KOH preparation, a fungal culture can be sent for confirmation of the diagnosis.

Tzanck smears may be helpful in the diagnosis of infections caused by the herpes virus family. Use a blade to unroof a vesicle and swab the base with a cotton tipped applicator. Then, spread the material obtained from the base of the lesion onto a glass slide then heat fix. After fixation, apply any blue stain (Giemsa or Wright) and leave on for five minutes, after which time, wash the excess stain off. The finding of multinucleated giant cells indicates the presence of herpes simplex or herpes zoster/varicella virus; the Tzanck smear can not be used to distinguish among these three infections.^{8,9,15,27}

In a patient with suspected scabies, use a moistened scalpel blade to vigorously scrape a burrow or papule. Spread the scrapings onto a slide and examine under low power for evidence of mites (no distinguishable head with four pairs of legs, and bristles on its dorsal surface, see “Mite” Figure page 5).

The Wood light exam can be used to diagnose tinea capitis since hairs infected with microsporum will fluoresce blue green. Care must be exercised, since other dermatophyte infections will not fluoresce.¹⁵

Fungal Culture

The introduction of the dermatophyte test medium (DTM) in 1969 facilitated screening of patients with proposed pathologic fungal infections. DTM contains antibiotics (cycloheximide, gentamycin, and chlortetracycline) which inhibit saprophytic fungi and bacteria. The medium also contains phenol red as a color indicator. Dermatophytes, which metabolize nitroge-

nous ingredients in the medium (not glucose), result in alkaline byproducts being produced and a change of the indicator from yellow to red which is noted as early as 48 hours. This medium is up to 97% sensitive in identifying pathologic fungi.^{15,17-19}

Eczematous

Eczema, which is sometimes also called dermatitis, is manifested by erythema, edema, vesiculation, scaling, and pruritis. An adjective is added to specify the precise type of dermatitis, (e.g., atopic dermatitis, contact dermatitis, seborrheic dermatitis, etc). Acute eczema consists of erythema, edema, exudation, clustered papulovesicles, scaling, and crusting whereas chronic eczema is characterized by lichenification and hyperpigmentation.⁷⁻⁹

In order to reach an accurate diagnosis of an eczematous dermatitis, it is important to consider the age of the patient, the duration of the eruption, and the distribution of the rash.

A generalized, confluent rash is suggestive of an exfoliative dermatitis which can be a manifestation of an underlying drug reaction or systemic disease. Extensive eruptions where there are areas of noted uninvolved skin present a broader differential that includes atopic dermatitis, seborrheic dermatitis, scabies, pityriasis rosea, and contact dermatitis. A family or personal history of atopy, a history of flares and remittances, and pruritis are suggestive of atopic dermatitis. A diagnosis of seborrheic dermatitis would be made in infancy and post-pubertal patients. Scabies may closely resemble atopic dermatitis; however, family or close contact exposure might lead the examiner in the proper direction. If an eczematous process is localized, the differential includes contact dermatitis, nummular dermatitis, scabies, molluscum contagiosum, and dermatophyte infection. The diagnosis of contact dermatitis is made by the appearance and distribution of the rash and is aided by the history of contact with an irritant or allergen. Linear lesions would suggest rhus dermatitis. A coin shaped rash is suggestive of nummular dermatitis. However, if the lesion is scaly with elevated borders, it is likely due to tinea corporis (a KOH preparation may help with this differentiation). The age of the child is particularly helpful when evaluating the scaly scalp. In teens and newborns with cradle-cap, seborrheic dermatitis is a prime consideration, but in a child (two years until puberty), tinea capitis must be excluded.

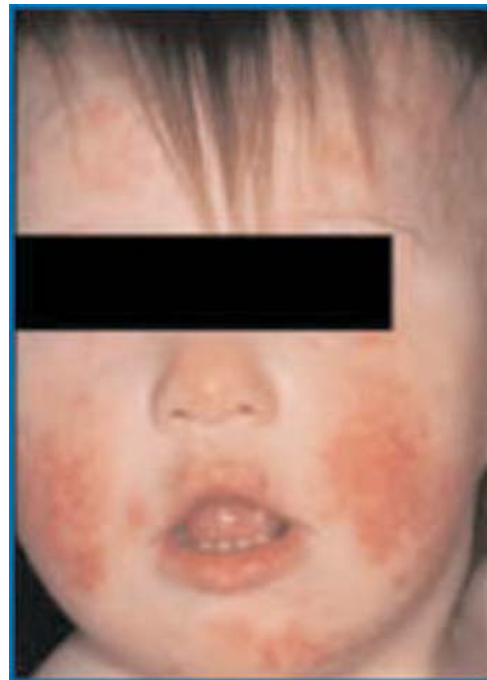When the eczematous process involves the hand and/or feet, the differential includes dyshydrotic eczema, contact dermatitis, or tinea pedis/manuum; a KOH prep may be essential.

Differential Diagnosis

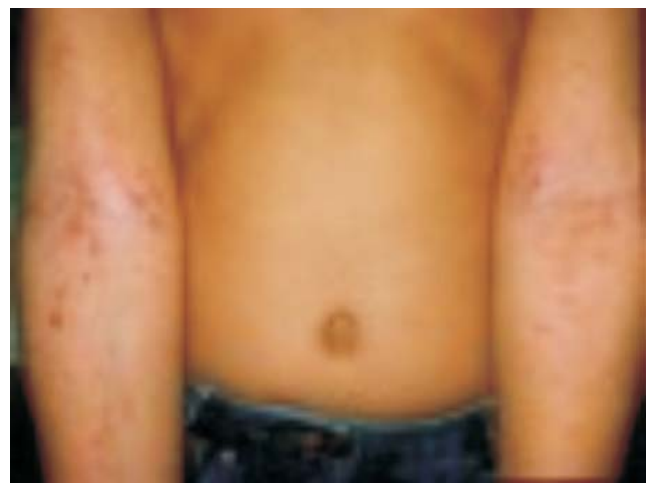Atopic Dermatitis²⁰⁻²²

Atopic dermatitis is an intensely pruritic, inflammatory condition that often occurs in children with a family history of atopic illnesses (asthma, rhinitis, conjunctivitis, and atopic dermatitis). Cookson and Hopkins^{21,22} studied the families of 20 asthmatics and, using IgE as a marker, suggested that the mode of inheritance of atopic dermatitis is autosomal dom-

Atopic Dermatitis



Atopic Dermatitis



inant. Dry skin is almost universal, especially during the winter months, and there is a distinct relationship between ichthyosiform scaling and atopic dermatitis in up to 50% of patients. Dennie-Morgan infraorbital folds, cheilitis, accentuated palmar creases, and periauricular fissures are nonspecific features of atopic dermatitis. In young infants, the face is the most common site of involvement and 50% of these children have resolution of dermatitis by three years of age. Closer to one year of age, the extensor surfaces of the extremities tend to have greater involvement. In older children and teenagers, the flexural surfaces of the extremities, the face, and the neck are typically involved. In about 30% of patients, atopic dermatitis begins on the hands, and 70% have hand dermatitis at some time. Sixty percent of affected individuals have onset of atopic dermatitis in their first year of life and 85% within the first five years.^{8,9,20} Walker and Warin²³ reported an incidence of 3% in a survey in 1956 and more recent studies indicate a marked rise in incidence since that time, with current estimates of 10% of the population being affected. This rising incidence of atopic dermatitis has made an impact on ED visits. In 1968, Wingert et al²⁴ reported that 4% of Los Angeles County ED visits were for atopic dermatitis, and a recent survey at the Children's Hospital of Philadelphia showed that 80% of the outpatient visits for atopic dermatitis during a one month period were to ED's.²⁵

A recent study showed that children with atopic dermatitis who were exposed to passive cigarette

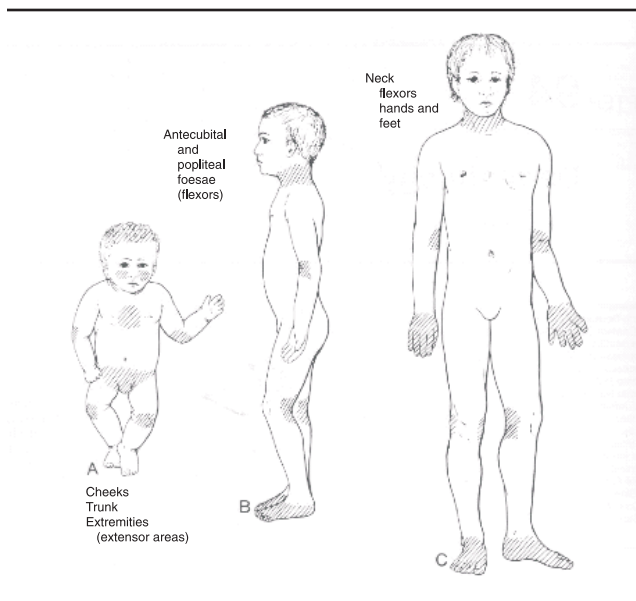
smoke had a significantly greater risk of developing asthma. Barker et al showed that nearly 60% of adults with atopic dermatitis with no prior history of respiratory disease have methacholine reactive airways.²⁶

A peculiar association of atopic dermatitis is the tendency toward early development of cataracts reportedly seen in 4 to 12% of patients. These cataracts appear in a much earlier period of life than senile cataracts. They mature rapidly and usually affect the central lens of both eyes. Studies have shown that long term use of corticosteroids in patients with atopic dermatitis is not the cause of this phenomenon.

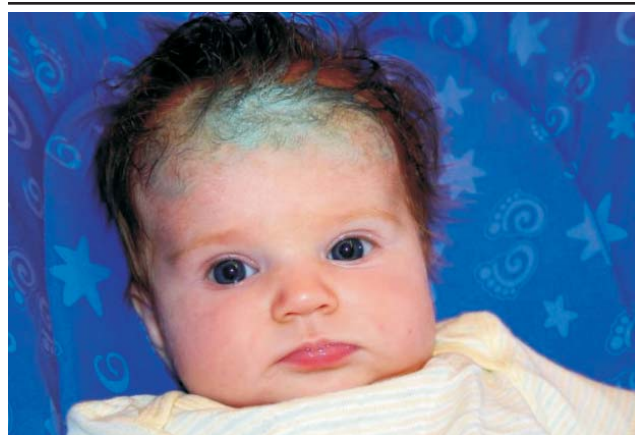Seborrheic Dermatitis

Seborrheic dermatitis can be distinguished from atopic dermatitis by milder pruritis and onset before two months of age. Another differentiating point is the involvement of the diaper area in seborrheic dermatitis.^{1,15,27} Seborrheic dermatitis is usually manifested by a salmon colored rash overlain by a greasy scale of the scalp ("cradle-cap"), forehead, nasal folds, and the diaper area. Often, a family history of atopy is lacking. Seborrheic dermatitis usually clears spontaneously by

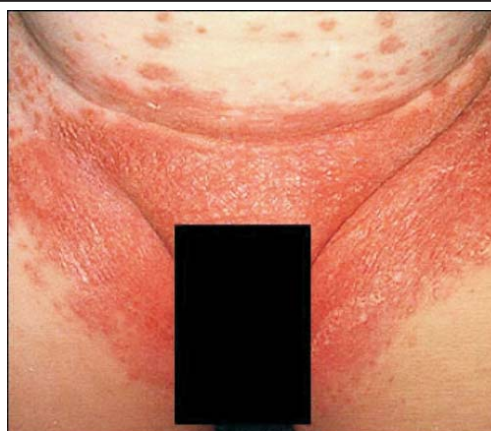Distribution Of Atopic Eczema At Various Ages



Seborrheic Dermatitis



Seborrheic Dermatitis

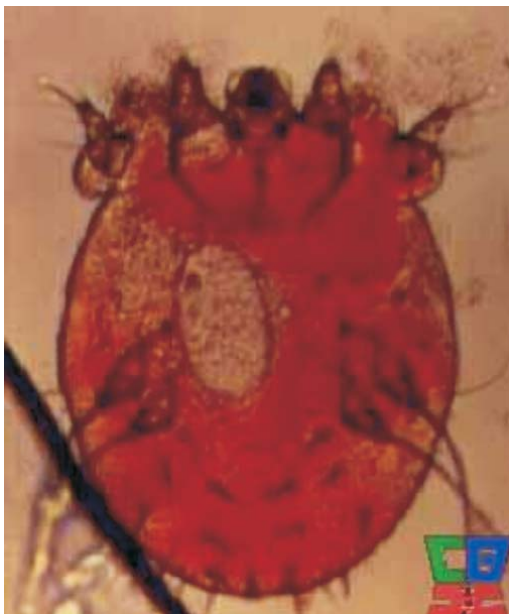

one year of age and generally doesn't recur until the onset of puberty. Between the period of infancy and adolescence, scaling of the scalp usually indicates causes other than seborrheic dermatitis, such as atopic dermatitis or tinea capitis. Seborrheic dermatitis during adolescence, similar to as seen in adults, is manifested by erythema and scaling on the scalp, eyebrows, eyelid margins, nasolabial creases, sideburns, beard, and mustache. Management is similar to that of atopic dermatitis, though anti-seborrheic shampoos (selenium sulfide) are used on involved scalp. In infants, loosening of the scalp scales using a fine toothed comb prior to shampooing hastens clearing. Since hairy locations are often affected, steroid preparations in the form of lotions or gels are preferred.

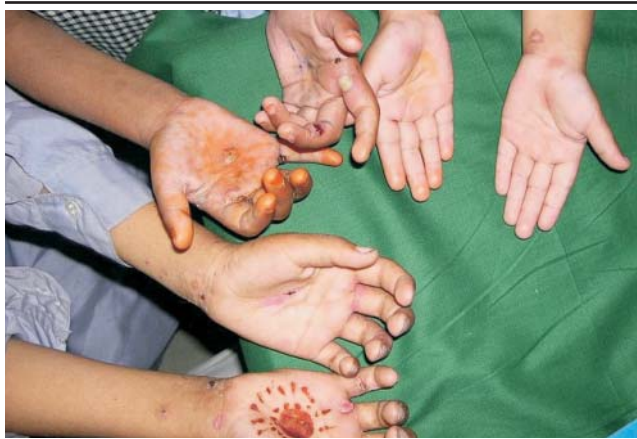Scabies

Scabies, an intensely pruritic papular or papulovesic-

Mite



Scabies



ular rash, is usually more prominent over the axillary and perineal regions as well as the hands and feet. Although only seen in a minority of cases, linear lesions (burrows) help clarify the diagnosis; the presence of symptoms in other family members helps differentiate this infestation from atopic dermatitis.

Nummular Dermatitis

Nummular dermatitis is a chronically occurring eruption of papulovesicular or papulo squamous, coin shaped lesions usually unrelated to atopy. Lesions are distributed on the extensor surfaces of the extremities. Classically, onset occurs later in childhood.²⁰

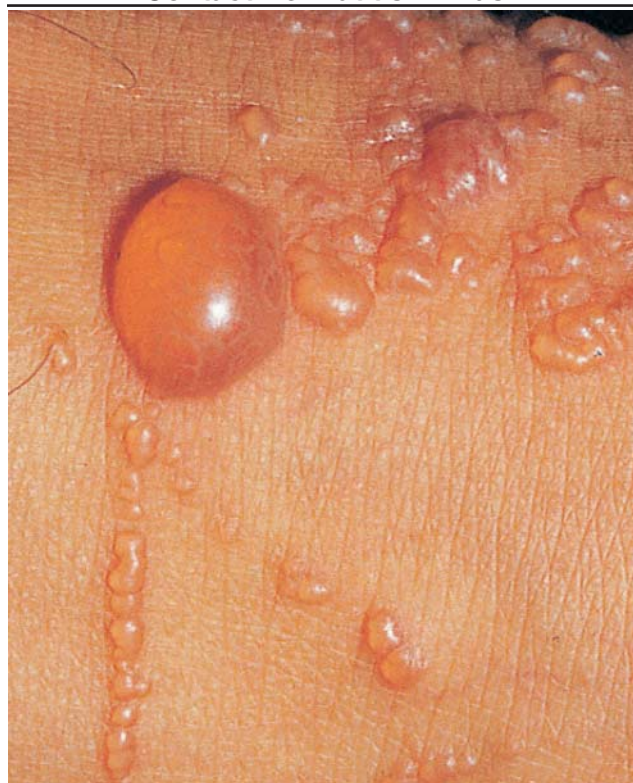
Dyshydrotic Eczema

Dyshydrotic eczema is a term used to describe a frequently recurring, symmetrically distributed, eczematous eruption on the palms, soles, and lateral aspects of the fingers and is characterized by inflammatory vesicles with associated burning or itching.

Contact Dermatitis

Contact dermatitis is relatively uncommon in children (incidence is 1.5% or one-eighth the incidence seen in adults) and patients with hand / foot dermatitis are often over diagnosed as having allergic contact dermatitis. Children less than one year of age rarely respond to contacts. In young children, contact dermatitis is typically found on the cheeks, chin (caused by drooling), and the diaper area (from urine

Contact Dermatitis - Rhus



and feces). Common substances that produce contact dermatitis include soaps, detergents, fiberglass, and bubble bath. Acute eruptions are characterized by intense linear or geometric areas of erythema accompanied by edema, papules, and vesicles with a sharp line of demarcation between involved and normal skin. Because skin involvement is limited to areas of contact, the distribution pattern and shape of the dermatitis provides important clues as to the causative agent.^{15-18,27}

There are a number of substances that cause contact dermatitis; see **Table 2**. A round lesion on the wrist would incriminate a wristwatch; a linear pattern encircling the waist points to the rubber in the waistband; linear lesions on exposed portions of the body indicate brushing against the leaves of poison ivy; extensive involvement of exposed areas of skin suggests an airborne allergen, such as ragweed. Poison ivy, poison oak, and poison sumac (*Rhus* plants) cause more cases of allergic contact dermatitis than all other contacts combined, followed by phenylenediamine, nickel (present in most alloys used in jewelry), and rubber compounds.^{1,2,8,9}

Seventy percent of the population will become sensitized if exposed to the oleoresin (known as urushiol) contained on the leaf, stem, or root of the *rhus* plant. The rash usually manifests two days after exposure as pruritic grouped or linear papulovesicles; see **"Contact Dermatitis - *Rhus*" Figure**. The eruption can last up to three weeks. Avoidance of exposure is the best prophylaxis but, once a patient is exposed, the best course of action is to remove and launder the clothing and bathe the patient. Nail polish containing formaldehyde is also a relatively common cause of allergic skin reactions. Phenylenediamine, which is contained in hair dyes, may cause an eczematous eruption on the scalp and face.^{15,20}

Table 2. Regional Predilection Of Various Substances That Cause Contact Dermatitis

- Scalp - hair dye, hair spray, shampoo
- Ear - Neomycin, earrings, perfume
- Forehead - hat band
- Eyelids - false eyelash cement, mascara, eye shadow/cosmetics
- Perioral - dentifrices, chewing gum
- Axilla - deodorant, clothing dye
- Breast - metal, elastic bra
- Wrist - cosmetic jewelry (nickel), leather (phenylenediamine, chrome)
- Waistline - rubber waistband, jockstrap, belt buckle, metal pants snap
- Feet - shoes

Psoriasis

Psoriasis lesions have a red hue and a loosely adherent silvery scale with a sharply delineated edge.

Psoriasis has a predilection for extensor surfaces of the elbows, knees, scalp, and perineum. A valuable clue in the diagnosis of psoriasis is the frequent presence of nail involvement seen in up to 50% of patients and other members in the family with this condition.^{8-10,15-18}

Acute Management

Topical medications are used frequently in the treatment of dermatologic disease and topical steroids comprise a large portion of the medications prescribed. They are classified according to potency, and different vehicles may change the potency of a particular steroid. Ointments have a higher oil-to-water ratio than creams and, therefore, provide a more effective barrier against moisture loss. Thus, medication in ointment form is generally more potent than the same medication in cream preparation. The occlusion of treated areas with polyethylene film (saran wrap) enhances the penetration of the corticosteroid up to 100 fold; this mode of therapy is typically reserved for lichenified or recalcitrant plaques. The penetration of topical steroids¹⁰⁻¹³ is inversely related to the thickness of the epidermis, requiring the use of a more potent preparation in areas where the skin is thick (palms and soles), while low potency varieties are indicated for use in regions where the skin is thin-

Table 3. Dermatitis Management

- Use topical corticosteroids for acute inflammation. Occasionally, a five day course of prednisone may be justified.¹⁰⁻¹⁹
- Apply emollients (petrolatum based: Nivea, Keri, Aquaphor, and Neutrogena) after bathing, while the skin is still moist, and throughout the day over the topical steroid. Fragrances and bubble baths should be avoided.
- Use antihistamines, such as hydroxyzine, diphenhydramine, loratidine, and cetirizine to control pruritis.²⁸⁻³⁰ Limit frequency of bathing and use moisturizing soaps (Dove, Tone).
- Use these antibiotics for superinfection: penicillinase resistant penicillin/dicloxacillin (recognize that this medication is often not palatable in liquid form), first generation cephalosporin, and macrolide. If MRSA is a concern, use sulphamethoxazole/ trimethoprim or clindamycin. Consider treating more severe case of eczema herpeticum with acyclovir.^{76,77}
- Patients can protect the skin against irritants by wearing long sleeve shirts and leotards. Remove known irritants, such as stuffed toys, wool clothing or blankets, or pets. Maceration of the skin can be avoided by keeping fingernails short.

ner (perineum and face). Less potent preparations are also indicated in settings where absorption of the steroid is likely to be enhanced, as might occur in patients with widespread dermatitis or those that require treatment of areas that are subject to anatomical (perineum/axillae) or diaper occlusion.¹⁰⁻¹²

Owing to their relatively thin cutaneous barrier, infants and young children should generally be treated with one of the lower potency topical steroids (1% hydrocortisone). Low to intermediate potency steroids (Group 4 to 7) are indicated for the initial management of eczematous dermatitis in older children and adolescents. High potency steroids are rarely required for the treatment of eczematous dermatitis in children, and super-potent preparations (Group 1) should not be used in children. For the majority of patients, topical steroids in a cream vehicle are both efficacious and cosmetically preferred. Lotion or gel based products are usually reserved for the treatment of hairy areas, such as the scalp.¹⁰⁻¹³

Emergency physicians must be aware of adverse effects, especially when using more potent formula-

tions or prolonged steroid application. Adverse effects include skin atrophy, rosacea, striae, and candidiasis. In addition, hypothalamic - pituitary - adrenal axis suppression due to systemic absorption may occur with prolonged topical steroid use over a large body surface area. Studies have shown little hypothalamic - pituitary - adrenal axis suppression with mid-potency agents. Only Group 7 topical steroids should be used for treatment of inflammatory conditions involving the face, axilla, and perineum.¹⁰⁻¹² A specific topical medication that should be avoided in children is Neomycin because of the high risk of contact sensitization.

The efficacy of antihistamines in atopic dermatitis remains uncertain. During a one week trial in children, Klein and Galant²⁹ showed that hydroxyzine produced a 30 to 50% reduction in pruritis, an effect that was significantly greater than with placebo. Much of the therapeutic benefit of antihistamines appears to be their sedative properties. Frosch et al³⁰ compared combined therapy with cimetidine and chlorpheniramine (H1 antagonist) to chlorpheniramine alone in 16 patients with atopic dermatitis; they failed to show any difference in pruritis. The non-sedating antihistamines appear to be less effective in controlling scratching.

Multiple studies have been conducted looking at the effectiveness of pimecrolimus,^{31-34,41-47} a selective nonsteroid inhibitor of inflammatory cytokines, in the management of atopic dermatitis. Schachner⁴⁶ et al evaluated the effectiveness of pimecrolimus 0.03% in 317 children ages two to 15 years with mild to moderate atopic dermatitis. Based upon a global atopic dermatitis assessment score at six weeks, 50.6% of the patients were treated successfully with pimecrolimus compared to 25.8% in the control group. Another study by Kaufmann⁴⁷ et al evaluated the effectiveness of pimecrolimus 0.1% in 129 patients with severe atopic dermatitis. Pimecrolimus reduced the dermatitis severity index at four weeks by 71.5% compared to an increase of 19.4% in the control group (P less than .001). In a study by Allen³³ et al looking at the systemic exposure and tolerability of pimecrolimus 0.1%, it was found that, in 81% of children, pimecrolimus blood concentrations were consistently below 1 ng/mL and more than half were below the assay limit of quantification of 0.05 ng/mL. The most common adverse event related to pimecrolimus was transient mild stinging at the application site. Lastly, a study by Reitamo⁴⁴ et al comparing the efficacy of pimecrolimus 0.03% and

Table 3: Steroid Classifications

| |
|---|
| Group 1 (Most Potent- Super Potent) Betamethasone dipropionate ointment 0.05% (Diprolene) |
| Group 2 (Very High Potency) Betamethasone dipropionate cream 0.05% (Diprolene) Mometasone furoate ointment 0.1% (elocon) Fluocinonide ointment or cream 0.05% (Lidex) Halcinonide ointment or cream 0.1% (Halog) |
| Group 3 (High Potency) Fluticasone propionate ointment 0.005% (cultivate) Betamethasone valerate ointment 0.1% (valisone) Triamcinolone acetonide ointment 0.5% (kenalog/aristocort) |
| Group 4 (Upper mid-Potency) Mometasone furoate cream 0.1% (elocon) Triamcinolone acetonide ointment 0.1% (kenalog aristocort) Hydrocortisone valerate ointment 0.2% (westcort) Flurandrenolide ointment 0.05% (cordran) |
| Group 5 (Mid-Potency) Fluticasone propionate cream 0.005% (cultivate) Triamcinolone acetonide cream 0.1% (kenalog/aristocort) Hydrocortisone valerate cream 0.2% (westcort) Betamethasone valerate cream 0.1% (valisone) Flurandrenolide cream 0.025% (cordran) Halcinonide cream 0.025% (Halog) |
| Group 6 (Low Potency) Desonide 0.05% ointment or cream (tridesilon) |
| Group 7 (Least Potent) Hydrocortisone cream or ointment 1% |

0.1% verses hydrocortisone 1% showed that both concentrations of pimecrolimus were more effective than hydrocortisone (P less than 0.001).

Pimecrolimus 0.1% was more effective than pimecrolimus 0.03% (P less than 0.006).

Atopic dermatitis's relationship with food hypersensitivity has been a subject of confusion for some time. In a study of a selected population of children with eczema, up to 60% had evidence of food hypersensitivity.³⁵ This was based on double blind, placebo controlled food challenges. Another study based on double blind, placebo controlled food challenges was conducted by Bock and Atkins³⁶ and carried out for over a 16 year period in 480 children. Thirty-nine percent of the children with a history of adverse reactions to food had documented adverse reactions (urticaria, erythematous rashes, gastrointestinal or respiratory complaints) on challenge. Reactions to food challenges were evident within two hours after ingestion. Approximately 75% of positive challenges were to eggs, peanuts, and cows milk. It should be recognized that the studies cited above may have overestimated the incidence of food allergy induced dermatitis since the study population was restricted to a university based referral clinic where children with more severe dermatitis are managed. It is likely that less than 10% of all children with atopic dermatitis and possibly 20% of those who have severe disease have relevant food allergy. Sampson and Jolie³⁷ showed a correlation between positive food challenges and increased plasma histamine levels 30 minutes after food ingestion. However, histamine-related reactions are often urticarial in nature and eczematous reactions can not typically be documented. The frequency of well defined eczematous reactions after food challenge remains to be established. Sampson and Scanlon³⁸ followed children placed on a food avoidance diet after documentation of food hypersensitivity. After one year, 25% of the children lost all signs of clinical food hypersensitivity. After two years, an additional 11% were no longer hypersensitive. Serum IgE and positive skin tests were not predictive of loss of symptoms; however, negative skin tests have a 90% negative predictive value.³⁹⁻⁴⁰

The skin of patients with atopic dermatitis appears to be susceptible to certain infections, partly because of mild immune dysfunction and partly because scratching and excoriation spread the infection. *Staphylococcus aureus*, group A streptococcus, herpes simplex (kaposi's varicelliform eruption), simple warts, and molluscum contagiosum are the most

common agents. Studies reveal a staphylococcus colonization rate of 93% on atopic dermatitis lesions and a colonization rate of 76% on normal skin.

The natural course of atopic dermatitis suggests a general tendency toward resolution with age. Longitudinal studies of 15- to 24-year-olds have shown clearing rates of 40%, but those with severe atopic dermatitis are twice as likely to have persistent disease. Cases persisting or beginning in the third decade of life have little tendency to spontaneously cure.

Infections / Exanthems

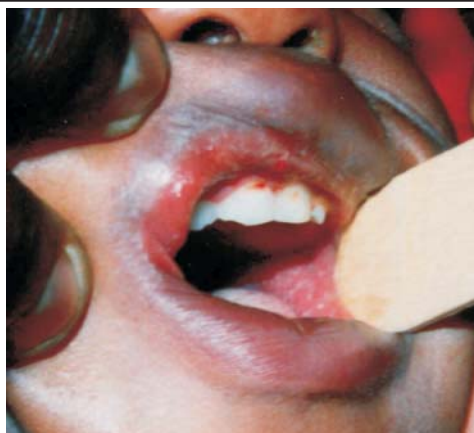Historically, before their etiologies were known, common exanthems were described by numbers: first disease: measles (rubeola), second disease: scarlet fever, and third: rubella. The fourth disease has been relegated to historical oblivion. The fifth disease (erythema infectiosum) is caused by parvovirus B19; the sixth (roseola) is caused by human herpes virus 6. Though there are more than 50 viral agents and several bacterial and rickettsial infections that may cause an exanthem, this discussion will be limited to the most common and clinically significant ones.

Viral

Measles^{48,49}

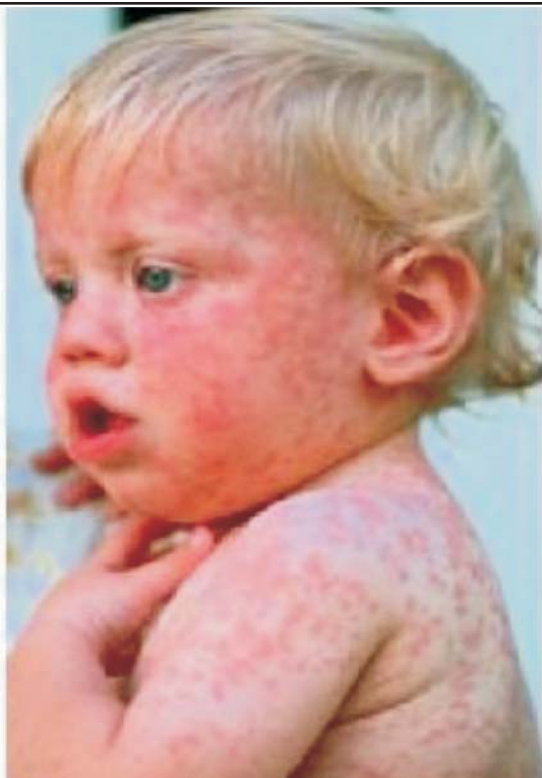Prior to 1963, measles was the most common viral exanthem of childhood, but in the U.S., measles became a relatively rare disease, with a precipitous decline with vaccine licensure.⁵⁰⁻⁵² However, epidemics began to reoccur in the late 1980's, with 17,000 cases reported in 1989. To address this issue, a two-vaccine schedule for measles (15 months and four to six years of age) is recommended. Anders⁵¹ et al documented the "failure rate" of live attenuated

Measles



measles vaccination administered to 2031 children older than 12 months of age to be less than 0.2% (95% CI 0 - 0.147%). Measles occurs in winter and spring with an incubation period of one week. Illness is manifested by a prodrome of three days with systemic toxicity, prostration, high fever, coryza, headache, photophobia, dry hacking cough, and impressive conjunctivitis. Koplik's spots, the pathognomonic enanthem of measles, appear on the buccal mucosa opposite the molars during the prodromal period and fade within three days after the onset of the rash. This nonpruritic exanthem begins behind the ears and rapidly spreads caudad. As the rash spreads, the discrete macules coalesce to produce a confluent rash. After one week, the rash fades. Attenuation of the illness occurs in children with partial immunity (those who received a vaccine).

Measles



Rubella^{27,48,49}

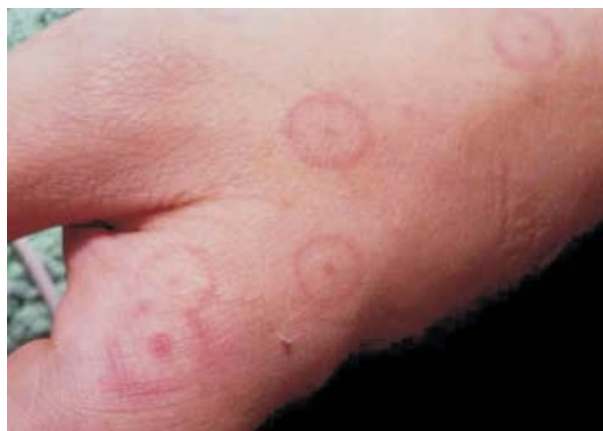In the U.S., rubella has remained a relatively rare disease, though sporadic outbreaks do occur. It produces a relatively mild illness associated with an exanthem. Its real danger lies in severe fetal infection that can develop if infection occurs during early pregnancy. In the first few weeks of pregnancy, the chance of transmission is 30 to 50%; at five to eight weeks, it is 25%, and from nine to 12 weeks, the risk is 8%. Incubation is two to three weeks and typically occurs during the spring. The prodrome consists of

malaise, cough, sore throat, low grade fever, headache, and a pink maculopapular rash that begins on the face with caudal progression. The rash tends to fade as it spreads and is typically gone by day four. Other clinical findings include suboccipital and postauricular adenopathy and arthralgia (in 25% of affected patients). Neutropenia is often present and serologic tests are used to confirm diagnosis. Unlike measles, where systemic toxicity and fever are the rule, fever is less common in rubella.

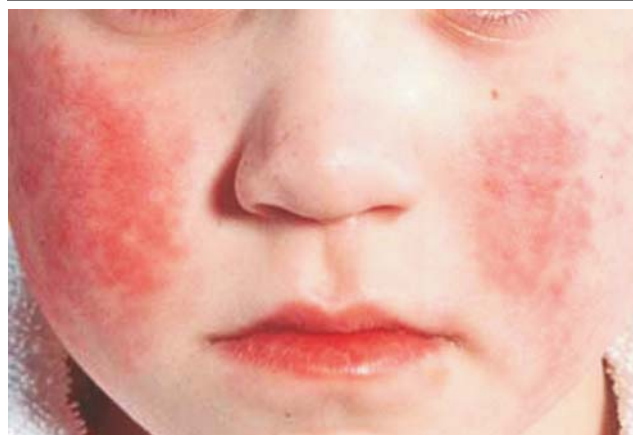Erythema Infectiosum (Fifth Disease)

Erythema infectiosum is a mildly contagious disease caused by human parvovirus B19. It typically affects school aged children (5 to 15 years of age).⁵³⁻⁶¹ The incubation period is usually one to two weeks with a prodrome consisting of low grade fever, malaise, and headache. A fiery red macular rash soon appears on the cheeks ("slapped cheek"), lasts one to four days, and is followed by a more generalized rash which evolves into a distinctive, lacy, reticular pattern most prominent on the extensor surfaces of the extremities. The rash may wax and wane for up to three weeks.

Erythema Multiforme



Erythema Infectiosum



Children with erythema infectiosum typically feel well but constitutional symptoms, such as headache, fever, sore throat, and coryza, occur in 5 to 15% of patients. Arthritis⁵⁸⁻⁶⁵ is the most common complication in adults but is unusual in children. Lastly, this infection is associated with transient aplastic crisis^{63,68} in patients with hemolytic anemias, hemoglobinopathies (particularly sickle cell disease),⁶⁹ or idiopathic thrombocytopenic purpura,^{57,62,70} as well as intrauterine infection and fetal death⁷¹ (risk ranges from 3 to 10%) in pregnant women infected during the first 20 weeks of gestation. Yoto et al⁷² reported epidemiological evidence suggesting that parvovirus B19 may be the cause of acute hepatitis. It should be noted that, when children have the rash of fifth's disease, they are no longer infectious.

Roseola^{27,48,49}

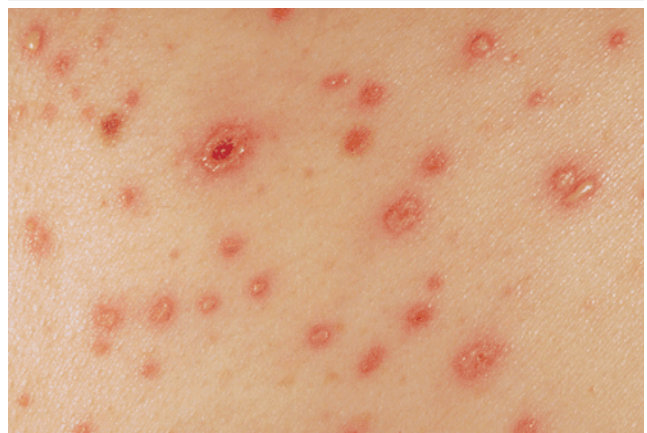Roseola is caused by human herpes virus 6 (the other five human herpes viruses, herpes simplex 1 and 2, varicella-zoster, cytomegalovirus, and Epstein-Barr virus are also known causes of skin eruptions). Roseola is the most common exanthem in children under age three. Virtually all cases occur between six months and three years of age, with most cases occurring before age one. It is estimated that 30% of children will develop this infection. The incubation period is one to two weeks and the illness classically presents with a fever of up to five days followed by precipitous defervescence and the appearance of a pink maculopapular rash on the neck and trunk. Despite the elevated temperature, affected children are bright-eyed and do not appear to be acutely ill. Roseola cases have also been documented without a preceding febrile illness. The duration of the rash lasts one to two days. Mild coryza, headache, and occipital/cervical/post-auricular adenopathy is common. Periorbital edema, when present in a febrile otherwise non-toxic child, is a useful clue during the pre-exanthematous stage. A common complication (seen in approximately 6% of cases) is febrile seizures.

Varicella^{48,49,73,74}

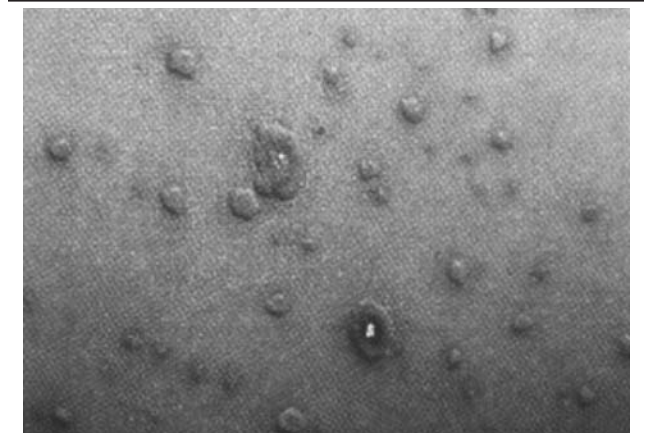
Varicella is a common and highly contagious systemic illness caused by the varicella-zoster virus. In the U.S., approximately 3.5 million people contract varicella each year. Half of the cases occur before age five and 90% by 15 years, with peak incidence in late winter and spring. After an incubation period of two to three weeks, the illness begins with a low grade fever and malaise. The characteristic skin eruption

begins as red macules that progress to discrete vesicles surrounded by erythema. The eruption typically begins on the face and trunk and spreads in successive crops centrifugally to the extremities over a week long period. It is often accompanied by significant pruritis. Lesions eventually crust over in five to ten days. The presence of lesions in varying stages of evolution and minimal distal extremity involvement helps to differentiate chickenpox from smallpox. Severe presentations of varicella may occur in children receiving steroids and immunocompromised patients. Such children are more likely to suffer extensive eruptions and varicella pneumonia. The Tzanck smear can demonstrate multinucleated giant cells and, in questionable cases, can be used to confirm the diagnosis. In most cases, management of varicella is directed at symptomatic relief of constitutional symptoms and ameliorating pruritis. Secondary bacterial infections, if present, should be treated with antibiotics directed against *Staphylococcus aureus*. Acyclovir may be effective in treating varicella and has been shown to prevent visceral dissemination in immunocompromised chil-

Varicella



Varicella



dren. A trial using oral acyclovir in otherwise healthy children produced modest results in terms of defervescence and lesion healing time.⁷³⁻⁷⁵ In a search of three articles on this topic, acyclovir was associated with a reduction in the number of days with fever (-1.1 days, 95% CI -1.3 to -0.9) and in reducing the number of lesions (-76 lesions, 95% CI -145 to -8 lesions). Results were less supportive with respect to the number of days to the relief of itching, and there was no clinically important difference between acyclovir and placebo with respect to complications associated with chickenpox. In summary, the clinical importance of acyclovir treatment in otherwise healthy children remains uncertain. Children with a history of chickenpox in the first year of life have a much higher incidence of zoster (shingles) in childhood (relative risk 2.8). The calculated incidence rate of zoster by 12 years of age in children who acquired varicella by one year of age in the Rochester study was 4.1 cases per 1000. A higher rate was noted in children who acquired varicella in the first two months of life: 12 cases per 1000.⁷⁴ An important point to consider is the association between vesicular lesions noted on the tip of the nose (involvement of the nasociliary branch of the trigeminal nerve) and possible ocular involvement.

Herpes Simplex

The most common presentation of primary herpes simplex in children (one to five years of age) is herpetic gingivostomatitis (HSV-1), but infection may also involve the eye (herpetic keratoconjunctivitis), the external genitalia (HSV-2), and fingers (herpetic whitlow). It should be noted, however, that oral HSV-2 and genital HSV-1 infections have become increasingly more common. Wrestlers are prone to spread herpes infection to one another, a condition

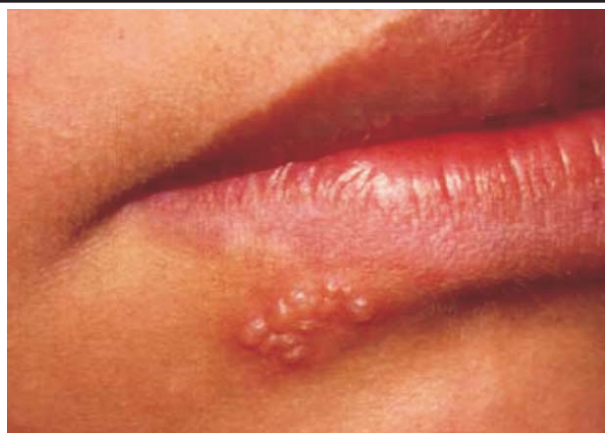called herpes gladiatorum.

Treatment⁷⁶⁻⁷⁷ is usually symptomatic, though acyclovir may be prescribed to shorten the course of more severe or recurrent disease. Recurrent HSV presents as grouped vesicles near the site of primary infection, and are often preceded by a burning or tingling sensation in the affected area. Triggering mechanisms responsible for reactivation include febrile illness, menses, stress, sunburn, or local trauma. Recurrent infection differs from primary infection in the smaller size of vesicles, their close grouping, and the usual absence of constitutional symptoms. Neonatal herpes usually develops when infants are delivered vaginally to mothers who have genital herpes. About half of these infected infants will have skin manifestations, and half of these, if untreated, will either die or suffer serious neurologic or ocular sequelae. Again, the Tzanck smear can demonstrate multinucleated giant cells and, in questionable cases, can be used to confirm diagnosis. Harel⁷⁷ et al conducted a randomized, double blind, placebo controlled study exploring the efficacy of acyclovir (15 mg/kg five times daily for seven days) in 72 children (ages one to six years) with confirmed *H. simplex* gingivostomatitis. Children who received acyclovir had oral lesions for a shorter period of time versus placebo (four vs. ten days, 95% CI 4 - 8) and earlier disappearance of fever (one vs. three days, 95% CI .8 - 3.2). Viral shedding was significantly shorter in the group treated with acyclovir (one vs. five days, 95% CI 2.9 - 5.1).⁷⁶⁻⁷⁷

Enteroviral Exanthems^{48,49}

Enteroviral exanthems are the most common summertime exanthems. This group of viruses was previously divided into coxsackie, echo, and polioviruses, but has now been unified within the picornavirus family. The age of the child at the time of infection appears to be significant in disease expression; exanthems are more common in younger children, whereas aseptic meningitis is more prominent in older children. The cutaneous manifestation is typically morbilliform, though vesicular and urticarial rashes have been reported. The incubation period typically lasts about one week and a prodrome is usually absent. Fever, upper respiratory infection, conjunctivitis, and vomiting/diarrhea are frequently seen. Common complications include pericarditis, myocarditis, pleurodynia, parotitis, hepatitis, pancreatitis, and encephalitis. Hand-foot-mouth disease, also caused by enteroviruses (most commonly coxsackie A16), is manifested by malaise and fever with oral vesicles

Herpes Simplex



(severe odynophagia with associated anorexia), followed by vesicles on the hands and feet. The diaper area may be affected in infants.

Epstein-Barr Infections

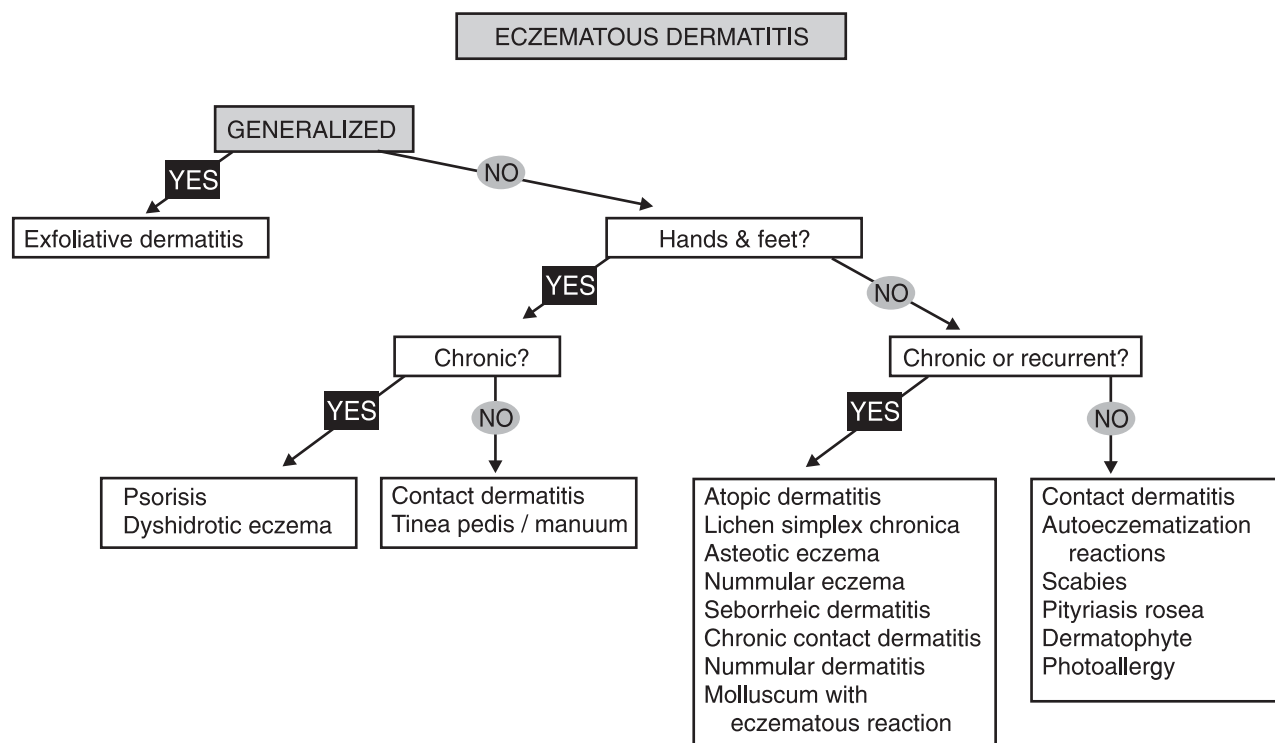
In young children, an exanthem is seen in as many as one-third of infected patients. Eighty to ninety percent of adolescents with mononucleosis develop a rash if amoxicillin/ampicillin is administered. After an incubation period of one to two months, acute infection begins insidiously with a high fever, congestion, odynophagia, adenopathy, and hepatosplenomegaly. The associated exanthem is usually maculopapular and facial; peripheral/periorbital edema may be present (in 50% of cases). The mono-spot test is unreliable in children younger than four years of age and if symptoms have been present for less than five days. Acute and convalescent EB viral titers and the finding of atypical lymphocytosis (seen in 70%) are supportive. It is purported that up to a quarter of children with EBV may have concurrent beta-hemolytic streptococcal infection. Prescribe a macrolide in this situation to avoid precipitating a rash.

Bacterial

Evaluation And Treatment

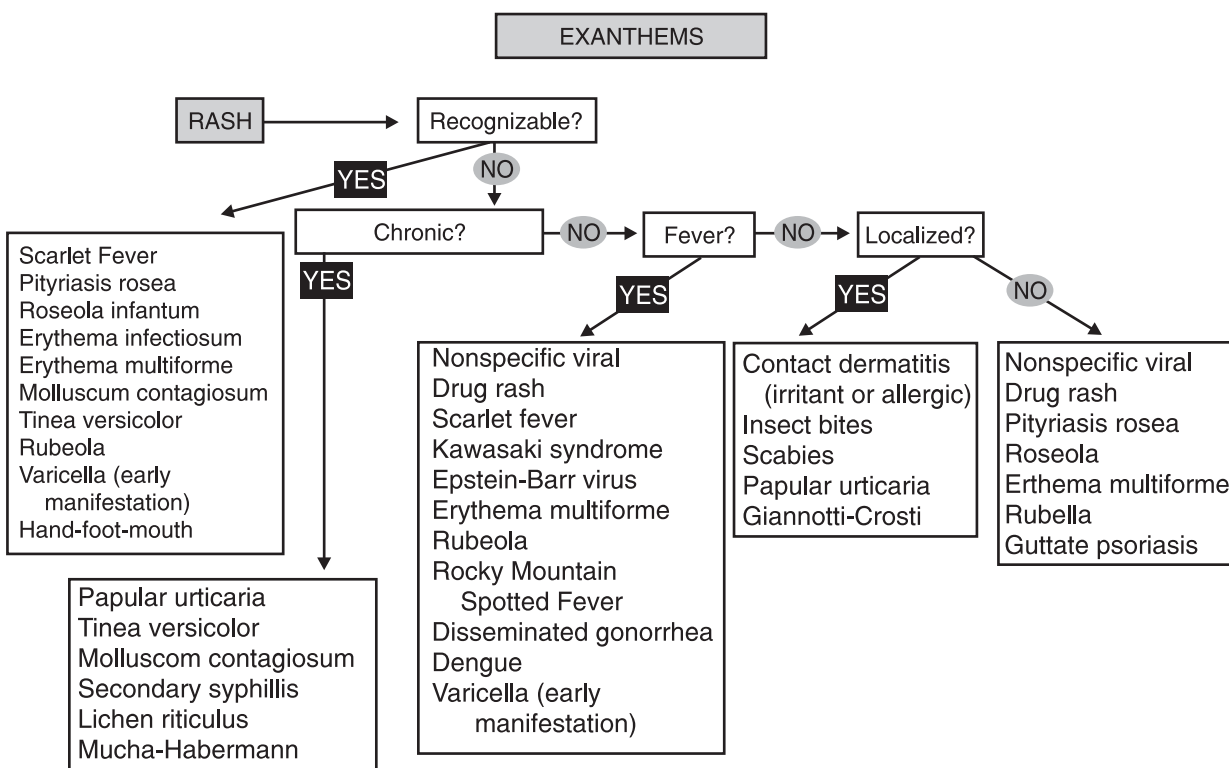
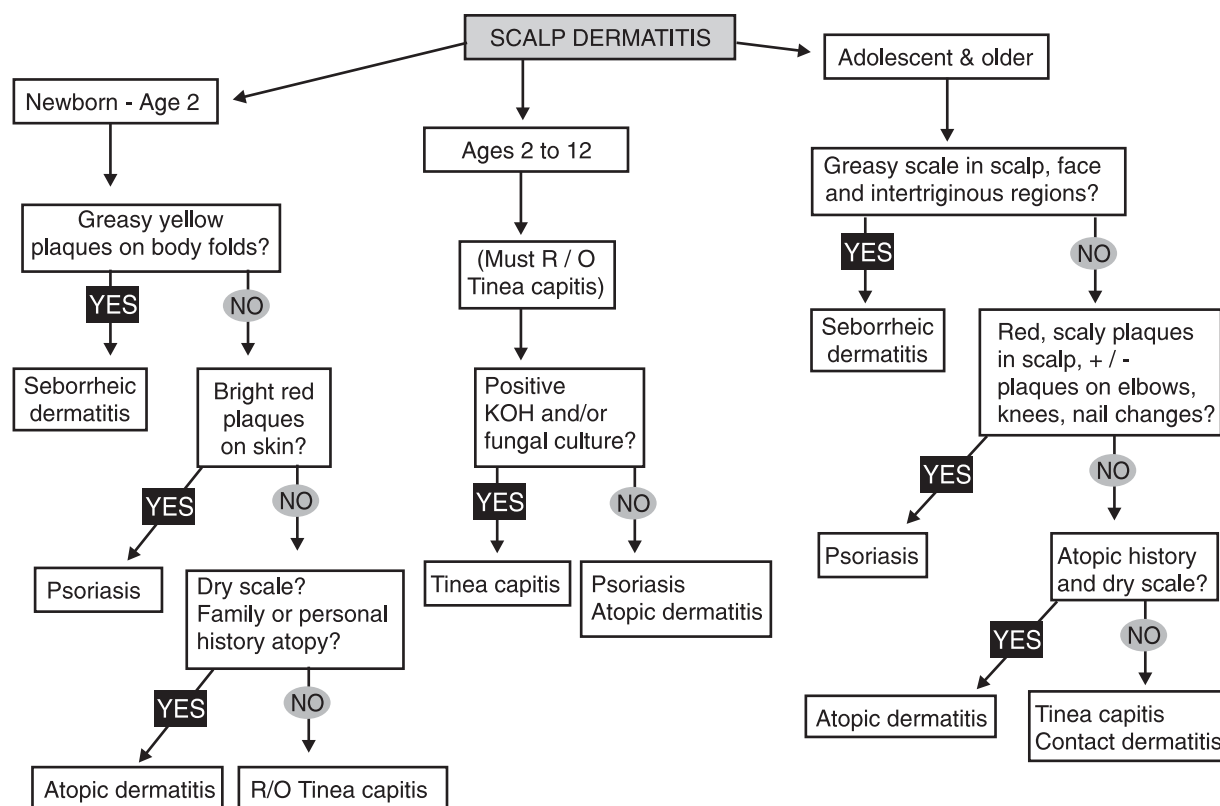
Staphylococcal Scalded Skin Syndrome (SSSS)^{78,79}

SSSS is a potentially life threatening, epidermolytic toxin mediated systemic manifestation of a localized infection with certain strains of *S. aureus*. Mellish and Glasgow injected coagulase positive staphylococci into mice; this produced erythema and a positive Nikolsky sign (extension of a blister or removal of epidermis after pressing is applied to the affected area) in 12 hours, followed by bullae and exfoliation in 20 hours. Though, at times, this disorder presents with a scarlatiniform erythroderma that does not progress to blistering; tender blistering and superficial denudation is more characteristic. SSSS is predominantly a disease of early childhood because children lack antibodies against the organism, and they are unable to metabolize and excrete the toxin as well as adults, most cases are seen before age five years. The cleavage plane for the skin sloughing in SSSS is epidermal as opposed to that seen in Toxic Epidermal Necrolysis (TEN) where the lower cleavage plane at the dermal-epidermal junction is associ-



This clinical pathway is intended to supplement, rather than substitute for, professional judgment and may be changed depending upon a patient's individual needs. Failure to comply with this pathway does not represent a breach of the standard of care.

Copyright © 2007 EB Practice, LLC. 1-800-249-5770. No part of this publication may be reproduced in any format without written consent of EB Practice, LLC.

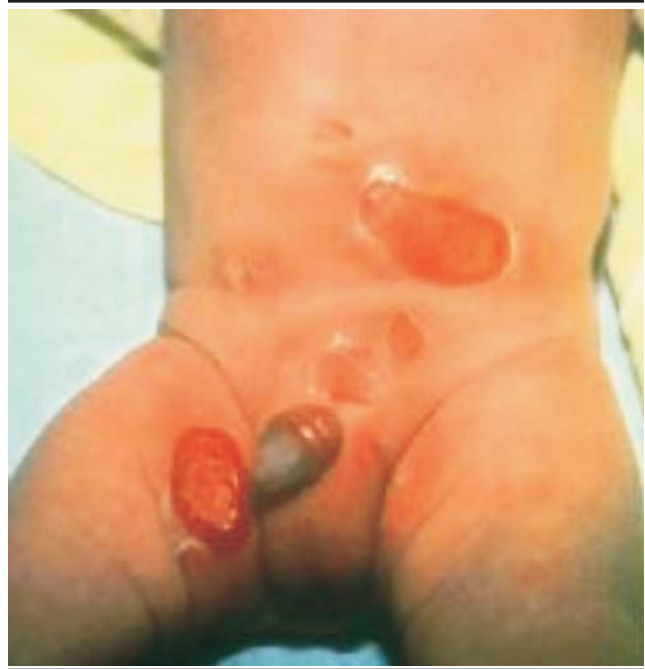

This clinical pathway is intended to supplement, rather than substitute for, professional judgment and may be changed depending upon a patient's individual needs. Failure to comply with this pathway does not represent a breach of the standard of care.

Copyright © 2007 EB Practice, LLC. 1-800-249-5770. No part of this publication may be reproduced in any format without written consent of EB Practice, LLC.

ated with higher morbidity. The sites of *S. aureus* infection typically involve the nasopharynx, umbilicus, urinary tract, or blood. Sudden onset of fever, irritability, cutaneous tenderness (infant does not want to be held), and scarlatiniform erythema (especially with perioral, periorbital, and neck involvement) herald the syndrome. Flaccid blisters typically develop within two days. Nikolsky's sign and lack of mucous membrane involvement are important clues to the diagnosis. Therapy is directed toward the elimination of the infection with anti-staphylococcal antibiotics, supportive skin care, and attention to fluid and electrolyte management; this will usually ensure recovery within two weeks, leaving no residua. Any child who is toxic or has severe skin involvement with marked denudation should be admitted to the hospital. As in patients with burns, secondary infection is an important consideration.

SSSS



Pitfalls To Avoid

1. "The only ocular consideration in children with atopic dermatitis is Dennie-Morgan pleats and allergic conjunctivitis."

A peculiar association of atopic dermatitis is the tendency toward early development of cataracts reportedly seen in 4 to 12% of patients. These cataracts appear much earlier in life than senile cataracts. They mature rapidly, and usually affect the central lens of both eyes. Studies have shown that long term use of corticosteroids is not the cause of this phenomenon in patients with atopic dermatitis.

2. "Contact dermatitis is as common in children as it is in adults."

Contact dermatitis is relatively uncommon in children (incidence is 1.5% or one-eighth the incidence seen in adults) and often patients with hand - foot dermatitis are over-diagnosed as having allergic contact dermatitis. Children less than one year of age rarely respond to contacts.

3. "The management of recalcitrant atopic dermatitis is limited to doses of increasingly potent topical and systemic steroids."

Multiple studies have been conducted looking at pimecrolimus, a selective nonsteroid inhibitor of inflammatory cytokines effective in the management of atopic dermatitis.

4. "Children with atopic dermatitis are only vulnerable to secondary bacterial infections due to scratching."

The skin of patients with atopic dermatitis appears to be susceptible to certain infections partly because of

mild immune dysfunction and partly because scratching and excoriation spread the infection. *Staphylococcus aureus*, group A streptococcus, herpes simplex (kaposi's varicelliform eruption), simple warts, and molluscum contagiosum are the most common agents.

5. "Acyclovir is a very effective form of treatment in children with chickenpox."

Acyclovir may be effective in treating varicella and it has been shown to prevent visceral dissemination in immunocompromised children. A trial using oral acyclovir in otherwise healthy children produced only modest results in terms of defervescence (a reduction in the number of days with fever by little more than a day) and number of lesions (reducing the number of lesions by fewer than 80 lesions). Results were less supportive with respect to the number of days to the relief of itching and there was no clinically important difference between acyclovir and placebo with respect to complications associated with chickenpox. In summary, the clinical importance of acyclovir treatment in otherwise healthy children remains uncertain.

6. "There is no difference in the way rashes present in African Americans compared to Caucasians."

Common cutaneous disorders may present differently in African American patients, e.g., when compared with Caucasians, the lesions of atopic dermatitis in African Americans often occur on the extensor rather than flexor surfaces, are grey rather than erythematous, and are more elevated in appearance. Hypo and hyperpigmentation are seen frequently in African American patients with atopic dermatitis.

Staphylococcal Toxic Shock Syndrome (TSS)⁸⁰⁻⁹⁹

Staphylococcal Toxic Shock Syndrome is caused by localized infection or colonization with certain strains of *S. aureus* and has occurred most commonly in menstruating girls using tampons. Changes in the manufacturing and use of tampons led to a decline in staphylococcal TSS over the past decade, while the incidence of non-menstrual staphylococcal TSS increased. Non-menstrual TSS^{80,86} and menstrual TSS are now reported with almost equal frequency. A TSS-like illness caused by group A beta-hemolytic streptococcus has been reported in multiple case reports (especially in association with varicella).^{82-85,90-}

^{93,97} Toxins produced by staphylococcus and streptococcus act as super-antigens that can activate the immune system by bypassing the usual antigen-mediated immune response sequence. The focal infections reported in association with TSS include empyema, osteomyelitis, peritonsillar abscess, cellulitis, surgical wound infection (including postpartum infection), insulin infusion site, infection in diabetics, and ear piercing.⁹⁵ In one study, 14 of the 57 reported cases of non-menstrual TSS in children occurred in the setting of an upper airway infection, such as bacterial tracheitis^{96,98} or sinusitis. (Please see the September 2006 *Pediatric Emergency Medicine Practice* issue, "A Killer Sore Throat: Inflammatory Disorders of the Pediatric Airway" for management and treatment of these diseases). Based on the Edwards-Jones⁹⁹ study of 14 children who developed

TSS in two British burn units, children with burns appear to represent a group at relative risk. TSS characteristically presents with abrupt onset of high fever associated with vomiting, diarrhea, headache, profound myalgia, strawberry tongue, conjunctival injection, and significant hypotension. Potentially fatal complications include refractory shock, renal failure, DIC, and ARDS. Cutaneous manifestations are prominent in TSS and include a flexurally accentuated scarlatiniform exanthem which initially appears on the trunk but generally spreads to the arms and legs. Edema of the palms and soles is common and desquamation of the hands and feet is usually seen within three weeks of presentation.

Reversible alopecia and shedding of fingernails has been described in 25% of patients with TSS. For strict definition, each of the first four criteria detailed in **Table 5** must be met and organ system dysfunction in three areas as shown in criterion.

According to Reingold, the reported case fatality rate in children has fallen from 15% to 3% since the early reporting of TSS,¹⁰⁰ considerably lower than the mortality rate in adults (30 to 80%). In spite of the national publicity over linkage with specific tampon usage, data regarding this linkage is relatively poor, and suggestions that changes in the choice or use of tampons will prevent TSS are unproven. Early recognition of this disease is important, because the clinical course is fulminant and the outcome depends on the prompt institution of therapy. Management of the child with TSS includes hemodynamic stabilization and appropriate antimicrobial therapy to eradicate the bacteria. Supportive therapy, aggressive fluid resuscitation, and vasopressors remain the main elements. Further research is being conducted looking at agents that block super-antigens, such as intravenous immunoglobulin that contains super-antigen neutralizing antibodies.

Streptococcal Scarlet Fever (SSF)⁴⁸⁻⁴⁹

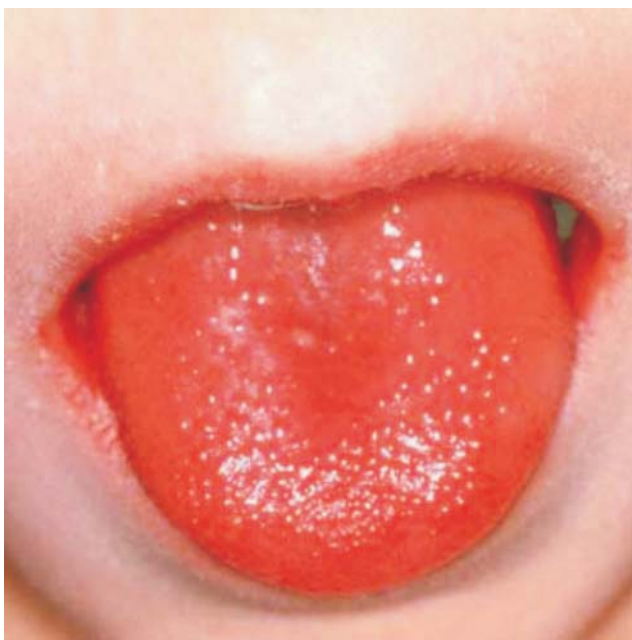SSF is caused by a phage infected, pyogenic exotoxin-producing group A beta-hemolytic streptococcal infection; SSF occurs predominantly in young children (age less than 10 years) and is associated with pharyngitis. It presents with abrupt onset of fever, headache, vomiting, andodynophagia. An enanthem develops with bright red oral mucous membranes, palatal petechiae, and a strawberry tongue. A flexurally accentuated (Pastia's lines) exanthem develops one to two days after the onset of the fever and has a sandpaper-like texture. Facial flushing with circum-

Table 5. Toxic Shock Syndrome: Case Definition

1. Fever greater than 38.9°C
2. Diffuse macular erythroderma
3. Desquamation one to two weeks after onset of illness, especially on palms and soles
4. Hypotension (systolic blood pressure less than fifth percentile)
5. Involvement of three or more organ systems:
 - Gastrointestinal (vomiting or diarrhea)
 - Muscular (severe myalgia or CPK greater than two times normal)
 - Mucous membranes (vaginal, oropharyngeal, or conjunctival hyperemia)
 - Renal (BUN or creatinine greater than two times normal)
 - Hepatic (total bilirubin, SGOT or SGPT greater than two times normal)
 - Hematologic (platelets less than 100,000)
 - Central Nervous System (altered mental status without focal neurologic signs)
6. Negative results on the following tests:
 - Throat, CSF cultures
 - Serologic tests for rocky mountain spotted fever or measles

oral pallor is often apparent. In dark-skinned individuals, the exanthem is often only visible on the palms and soles, where pigmentation is less pronounced. In other areas, the rash may be difficult to appreciate and has the texture of "goose flesh." The exanthem resolves in five days. Postexanthematous desquamation, especially on the palms and soles, begins as the rash fades after two weeks. The diagnosis of SSF is made by identifying the characteristic clinical features along with isolating the group A streptococcal infection from the pharynx. It should be noted that a similar syndrome, staphylococcal scarlet fever, has also been described. It closely resembles streptococcal scarlet fever from which it can be differentiated by the absence of streptococcal disease and the lack of desquamation. Penicillin (macrolide if allergic) remains the treatment of choice for streptococcal scarlet fever and beta-lactamase-resistant penicillin for the staphylococcal variant.

Scarlet Fever Tongue



Meningococcemia

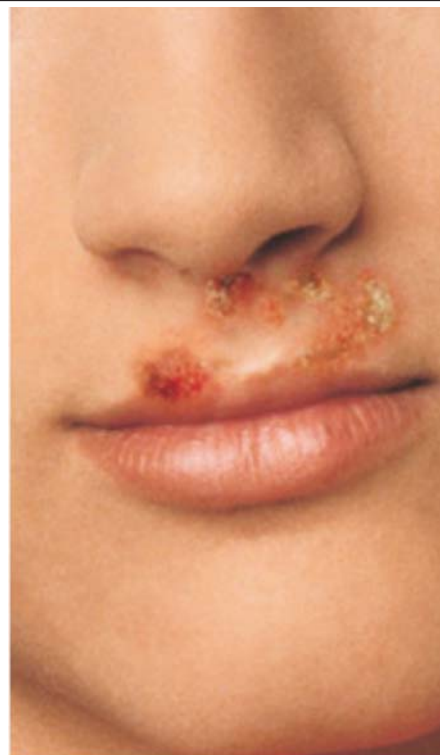Meningococcemia may present with an influenza-like illness with fever, myalgia, arthralgia, and a prominent cutaneous eruption (in two thirds of patients). The eruption consists of morbilliform macules and papules, leading to confusion with viral exanthems. Petechial or purpuric lesions are more typical in meningococcemia and may be indistinguishable from the lesions of gonococcemia. The trunk and lower extremities are the most common affected sites but petechiae may also appear on the face, palms, and mucous membranes. More extensive hemorrhagic lesions are seen in fulminant meningococcemia and a

progressive increase on all areas of the body may be followed by coalescence of lesions to form large ecchymotic areas. Rapid diagnosis can be accomplished by identifying the gram negative diplococcus from gram stained material obtained from characteristic petechial lesions. A prospective study of fever and petechiae in 190 children found that invasive bacterial disease (including meningococcemia) was more likely when the petechiae involved the lower extremities; no child with petechiae only above the nipples had invasive bacterial disease. If meningococcemia is suspected and the child is clinically stable, obtain blood and CSF cultures, start IV penicillin, and hospitalize the patient.

Impetigo

Impetigo is the most common cutaneous infection in children and is caused by staphylococcus or streptococcus. Impetigo, most commonly seen in late summer and early fall, is highly contagious and spreads readily over the skin surface of affected children. Children of preschool age are typical victims, particularly those who have sustained bites, abrasions, and lacerations. It is more common in warm humid climates, thus, children living in the southern U.S. are more commonly affected. It begins as small painless macules, commonly near the nose and mouth, which then progress to blisters. The blisters may rupture, releasing a serous fluid which dries to form the char-

Impetigo



acteristic honey colored crust. Topical antibiotics, such as mupirocin, are often sufficient; however, extensive lesions may be treated with oral anti-staphylococcal antibiotics. The nose is a reservoir for staphylococci in asymptomatic children, thus, intranasal mupirocin may be used for prophylaxis in patients who develop recurrent impetigo. A meta-analysis study by George et al¹⁰¹ demonstrated that topical antibiotics were more effective than placebo (OR 2.69, 95% CI 1.49 - 4.86). While *S. aureus* can be cultured from over half of impetiginous lesions in bullous impetigo, *S. aureus* is generally present in pure culture. The bullae are initially filled with a clear fluid which rapidly becomes cloudy. Bullae tend to spread locally, though this process may be accelerated when the cutaneous barrier is breached by varicella and insect bites. The thin blister roof is lost relatively early so that most lesions dry up quickly without the build-up of debris and crusts. Acute glomerulonephritis is the most significant complication of

streptococcal impetigo, though this is uncommon. On the other hand, the risk of developing nephritis following skin infection with a nephritogenic strain of strep is up to 28%. Lastly, although systemic antibiotics help eliminate cutaneous strep, they do not appear to prevent glomerulonephritis.

Folliculitis

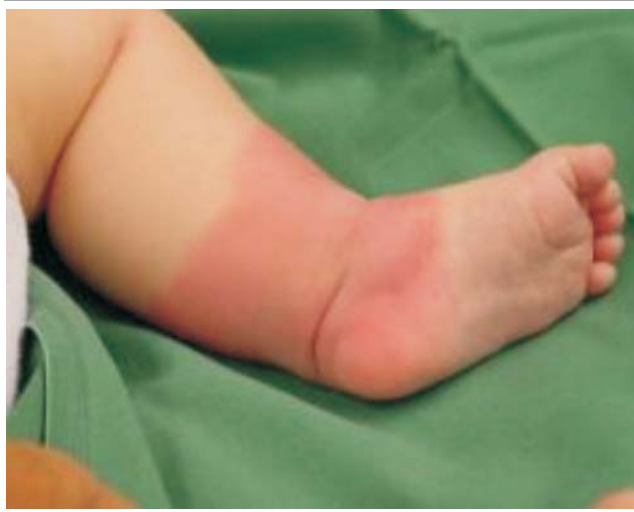Folliculitis is an infection of the hair follicles and is usually caused by staphylococcus. Folliculitis most commonly involves the scalp, face, buttocks, and extremities in children. Clinically, it appears as follicular erythematous papules and pustules. Treatment entails bathing with antibacterial soaps and the application of topical antibiotics, though systemic anti-staphylococcal antibiotics may be required for persistent or recurrent cases.

| Disease | Usual Age | Season | Morphology | Distribution | Associated Findings |
|----------------------------|----------------------|-----------------|--|--|--|
| Rubeola | infant - young adult | winter - spring | confluent erythematous macular papular | begins on the face spreads caudad | Kopliks spots, toxic appearance, cough, fever |
| Rubella | young adults | spring | non confluent pink papules | begins on the face spreads caudad | postauricular / occipital adenopathy, headache |
| Fifth's Ds | 5 to 15 years | winter - spring | slapped cheek, reticulate erythema / macular papular | usually arms / legs, may be generalized | wax / wane rash over several weeks, arthritis, headache |
| Roseola | 6mo to 3 Years | spring - fall | macular papular rash when fever declines | trunk, may be generalized | postauricular adenopathy |
| Varicella | 1 to 14 years | winter - spring | vesicles on an erythematous base, then crusts | begins on scalp / face, spreads to trunk, then extremities | pruritic |
| Enteroviral | young | summer - fall | macular papular | usually generalized | myocarditis, aseptic meningitis, pleurodynia |
| Adenovirus | 5 months to 5 years | winter - spring | morbiliform | generalized | URI |
| EBV | young - teen | any | morbiliform | trunk, extremities | post cervical, hepatosplenomegally |
| Staph scalded skin | neonates and infants | any | acute tender erythroderma | diffuse | conjunctivitis, rhinitis |
| Toxic shock | teens | any | erythroderma | generalized | hypotension, myalgia, vomiting, diarrhea |
| Scarlet Fever | school age | fall - spring | diffuse erythema, sandpaper texture | facial with circumoral pallor, linear erythema in skin folds | exudative pharyngitis, palatal petechiae, abdominal pain |
| Meningococcemia | less than 2 years | winter - spring | petechiae, purpura | trunk, extremities, palms, Soles | meningismus, shock |
| Rocky Mt Spot Fever | any | summer | maculopapular, petechial | wrist, ankle, palms, soles, trunk later | CNS, pulmonary, cardiac involvement |

Erysipelas

Erysipelas is a distinctive form of cellulitis caused by group A beta-hemolytic streptococcus. Erysipelas begins as a tense, painful, bright red plaque which spreads rapidly with distinct elevated borders. The skin is indurated, shiny, and warm. Although this infection has a predilection for the face in adults, erysipelas may involve any part of a child's body, though the extremities are most commonly affected. The onset of fever and prostration may be abrupt and bacteremia is common. Penicillin is the drug of choice, though macrolides or clindamycin are alternatives.

Erysipelas



Cellulitis

While erysipelas is characterized by distinct borders, cellulitis caused by *S. aureus* and streptococcus tend to have indistinct non-elevated borders. It is characterized by erythema, swelling, and tenderness and usually occurs as a complication of a breach in the cutaneous barrier (trauma). Lymphangitis is common and regional lymphadenitis is frequently identified. Facial cellulitis in young children (ages three months to three years) is often caused by *Hemophilus influenza* type B. In 50% of cases, this form of cellulitis has a purplish hue. Children with facial cellulitis appear ill; in an article by Ginsberg et al,¹⁰³ two thirds of the 72 patients with facial cellulitis had otitis media, and blood cultures were positive for H. Flu in 86% as were 5 of 66 CSF cultures. Five studies looking at the effectiveness of conjugate vaccines for preventing H. Flu type B infections verified its safety and effectiveness.^{102,104}

Swelling and erythema of the soft tissues surrounding the eye is another important localized cellulitis of childhood. The potential to spread the infection into the orbit is a primary concern. Most com-

monly caused by staphylococcus and streptococcus, this infection follows sinusitis, most notably ethmoid sinusitis, which allows the spread of infection to the orbit when the lamina papyracea is breached. Orbital cellulitis is a much more serious infection and is manifested by ophthalmoplegia and proptosis. If clinical differentiation remains unclear, orbital CT is often required.

Summary

This concludes Part I of "Childhood Rashes That Present To The ED." Part II, covering fungal rashes, granuloma annulare, Kawasaki disease, insect related rashes, pediculosis, drug related hypersensitivity syndromes, pityriasis rosea, molluscum contagiosum, warts, and neoplastic diseases of the skin, will be published next month.

References

Evidence-based medicine requires a critical appraisal of the literature based upon study methodology and number of subjects. Not all references are equally robust. The findings of a large, prospective, randomized, and blinded trial should carry more weight than a case report.

To help the reader judge the strength of each reference, pertinent information about the study, such as the type of study and the number of patients in the study, will be included in bold type following the reference, where available.

1. Gupta, A., Rasmussen, J. What's new in pediatric dermatology. *Journal of the American Academy of Dermatology*. 18(2 Pt 1):239-59,1988. **(Review Article)**
2. Treadwell, P. Recent advances in pediatric dermatology. *Advances in Dermatology*. 2:107-26,1987. **(Review Article)**
3. Yan, A., Krakowski, A., Honig, P. What's new in pediatric dermatology: an update. *Advances in Dermatology*. 20:1-21,2004. **(Review Article)**
4. Sidbury, R. What's new in pediatric dermatology: update for the pediatrician. *Current Opinion in Pediatrics*. 16(4):410-4,2004. **(Review Article)**
5. Ruiz-Maldonado, R. Pediatric dermatology accomplishments and challenges for the 21st century. *Archives of Dermatology*. 136(1):84,2000. **(Review Article)**
6. Tunnessen, W. A survey of skin disorders seen in pediatric general and dermatology clinics. *Pediatric Dermatology*. 1(3):219-22,1984. **(Survey of office visits to a general pediatric clinic)**
7. Caputo, R. Recent advances in pediatric dermatology. *Pediatric Clinics of North America*. 30(4):735-48,1983. **(Review Article)**
8. Hanson, S., Nigro, J. Pediatric dermatology. *Medical Clinics of North America*. 82(6):1381-403,1998. **(Review Article)**
9. Brodtkin, R., Janniger, C. Common clinical concerns in pediatric dermatology. *Cutis*. 60(6):279-80,1997. **(Review Article)**
10. Chapel, K., Rasmussen, J. Pediatric dermatology: advances in therapy. *Journal of the American Academy of Dermatology*. 36(4):513-26,1997. **(Review Article)**
11. Rasmussen, J. Percutaneous absorption of topically applied triamcinolone in children. *Archives of Dermatology*, 114:

- 1165-7,1978. **(Prospective, randomized case-controlled trial; 7 patients)**
12. Weston, W., Sans, M., Morris, H. Morning plasma cortisol level in infants treated with topical fluorinated glucocorticosteroids. *Pediatrics*. 65:103-6,1980. **(Prospective, randomized clinical trial; 17 patients)**
13. Nicolaidou, E., Katsambas, A. Antihistamines and steroids in pediatric dermatology. *Clinics in Dermatology*. 21(4):321-4,2003. **(Review Article)**
14. Davis, A., Krafchik, B. New drugs in pediatric dermatology. *Current Opinions in Pediatrics*. 5(2):212-5,1993. **(Review Article)**
15. Hartley, A., Rabinowitz, L. Pediatric dermatology. *Dermatologic Clinics*. 15(1):111-9,1997. **(Review Article)**
16. Raimer, S. Controversies in pediatric dermatology. *Advances in Dermatology*. 9:193-203,1994. **(Review Article)**
17. Krowchuk, D., Tunnessen, W., Hurwitz, S. Pediatric dermatology update. *Pediatrics*. 90(2):259-64,1992. **(Summary of topics discussed at the section of dermatology of the American Academy of Pediatrics annual meeting)**
18. Eichenfield, L., Honig, P. New developments in pediatric dermatology. *Common Problems in Pediatrics*. 21(10):421-7,1991. **(Review Article)**
19. Eichenfield, L., Honig, P. Difficult diagnostic and management issues in pediatric dermatology. *Pediatric Clinics of North America*. 38(3):687-710,1991. **(Review Article)**
20. Boerio, M., Brooker, J., Freese, I., Phares, P., Yazvec, S. Pediatric dermatology: that itch scaly rash. *Nursing Clinics of North America*. 35(1):147-57,2000. **(Review Article)**
21. Cookson, W., Hopkins, J. Dominant inheritance of atopic immunoglobulin E responsiveness. *Lancet*. 1:86-8,1988. **(Prospective controlled clinical trial; 239 patients)**
22. Cookson, W., Faux, J., Hopkins, J. Linkage between immunoglobulin E responses underlying asthma and rhinitis and chromosome 11q. *Lancet*. 1:1292-5,1989. **(Case reports; 7 families)**
23. Walker, R., Warin, R. Incidence of eczema in early childhood. *British Journal of Dermatology*. 68:182-3,1956. **(Retrospective clinical study; 1024 patients)**
24. Wingert, W., Friedman, D., Larson, W. The dermatological and ecological characteristics of a large urban pediatric outpatient population and the implication for improving community pediatric care. *American Journal of Public Health*. 58:859-76,1968.
25. Murray, A., Morrison, B. It is a child with atopic dermatitis who develops asthma more frequently if the mother smokes. *Journal of Allergy & Clinical Immunology*. 86:732-9,1990. **(Clinical trial; 620 patients)**
26. Barker, A., Hanifin, J., Hirshman, C. Airway responsiveness in patients with atopic dermatitis. *Journal of Allergy & Clinical Immunology*. 87:780-3,1991. **(Randomized prospective clinical trial; 123 patients)**
27. Wiley H. Pediatric dermatology in primary care medicine. *Primary Care; Clinics in Office Practice*. 16(3):809-22,1989. **(Review Article)**
28. Raimer, S. New and emerging therapies in pediatric dermatology. *Dermatologic Clinics*. 18(1):73-8,2000. **(Review Article)**
29. Klein, G., Galant, S. A comparison of the antipruritic efficacy of hydroxyzine and cyproheptadine in children with atopic dermatitis. *Annals of Allergy*. 44:142-5,1980. **(randomized double-blind controlled trial; 20 patients)**
30. Frosch, P., Schwanitz, H., Macher, E. A double blind trial of H1 and H2 receptor antagonists in the treatment of atopic dermatitis. *Archives of Dermatological Research*. 276(1):36-40,1984. **(Randomized clinical trial; 18 patients)**
31. Papp, K., Werfel, T., Folster-Holst, R., Ortonne, J., Potter, P., deProst, Y., Davidson, M., Barbier, N., Goertz, H. Paul, C. Long term control of atopic dermatitis with pimecrolimus cream 1% in infants and young children: a two year study. *Journal of the American Academy of Dermatology*. 52(2):240-6,2005. **(Multicenter, randomized double-blind controlled trial; 91 patients)**
32. Smith, J., Brodell, R. Improved therapy for atopic dermatitis. New immunomodulators clear the rash with few side effects. *Postgraduate Medicine*. 115(1):35-7,2004. **(Case report; 1 patient)**
33. Allen, B., Lakhanpaul, M., Lateo, S., Davies, T., Scott, G., Cardno, M., Ebelin, M-E., Burtin, P., Stephenson, T. Systemic exposure, tolerability, and efficacy of pimecrolimus cream 1% in atopic dermatitis patients. *Archives of Diseases in Childhood*. 88(11):969-73,2003. **(Non-controlled clinical trial; 36 patients)**
34. Ho, V., Gupta, A., Kaufmann, R., Todd, G., Vanaclocha, F., Takaoka, R., Folster-Holst, R., Potter, P., Marshall, K., Thurston, M., Bush, C., Cherill, R. Safety and efficacy of non-steroidal pimecrolimus cream 1% in the treatment of atopic dermatitis in infants. *Journal of Pediatrics*. 142(2):155-62,2003. **(Multicenter, randomized double-blind controlled trial; 186 patients)**
35. Sampson, H., McCaskill, C. Food hypersensitivity and atopic dermatitis: Evaluation of 113 patients. *Journal of Pediatrics*. 107(5):669-75,1985. **(Controlled clinical trial)**
36. Bock, S., Atkin, F. Patterns of food hypersensitivity during sixteen years of double-blind, placebo controlled food challenges. *Journal of Pediatrics*. 117(4):561-7,1990. **(Controlled clinical trial)**
37. Sampson, H., Jolie, P. Increased plasma histamine concentration after food challenges in children with atopic dermatitis. *New England Journal of Medicine*. 311(6):372-6,1984. **(Controlled clinical trial)**
38. Sampson, H., Scanlon, S. Natural history of food hypersensitivity in children with atopic dermatitis. *Journal of Pediatrics*. 115(1):23-7,1989. **(Controlled clinical trial)**
39. Sampson, H., Albergo, R. Comparison of results of skin tests, RAST, and double-blind placebo controlled trial challenges in children with atopic dermatitis. *Journal of Allergy & Clinical Immunology*. 74:26,1984. **(Randomized double-blind controlled trial; 40 patients)**
40. Thompson, M., Hanifin, J. Effective therapy of childhood atopic dermatitis allays food allergy concerns. *Journal of the American Academy of Dermatology*. 53(2 Suppl 2):S214-9,2005. **(Retrospective study; 23 patients)**
41. Wahn, U., Bos, J., Goodfield, M., Caputo, R., Papp, K., Manjra, A., Dobozs, A., Paul, C., Molloy, S., Hultsch, T., Graeber, M., Cherill, R., deProst, Y. Efficacy and safety of pimecrolimus cream in the long term management of atopic dermatitis in children. *Pediatrics*. 110(1 PT 1):e2, 2002. **(Multicenter, randomized double-blind controlled trial; 713 patients)**
42. Wellington, K., Jarvis, B. Topical pimecrolimus: a review of its clinical potential in the management of atopic dermatitis. *Drugs*. 62(5):817-40,2002. **(Review Article)**
43. Eichenfield, L., Lucky, A., Boguniewicz, M., Langley, R., Cherill, R., Marshall, K., Bush, C., Graeber, M. Safety and efficacy of pimecrolimus cream 1% in the treatment of mild and moderate atopic dermatitis in children and adolescents. *Journal of the American Academy of Dermatology*. 46(4):495-504,2002. **(Multicenter, randomized controlled trial; 403 patients)**
44. Reitamo, S., Van Leent, E., Ho, V., Harper, J., Ruzicka, T., Kalimo, K., Cambazard, F., Rustin, M., Taieb, A., Gratton, D., Sauder, D., Sharpe, G., Smith, C., Junger, M., deProst, Y. Efficacy and safety of pimecrolimus ointment compared with that of hydrocortisone acetate ointment in children with atopic dermatitis. *Journal of Allergy and Clinical Immunology*. 109(3):539-46,2002. **(Multicenter, randomized double-blind controlled clinical trial - phase III; 560 patients)**
45. Boguniewicz, M., Fiedler, V., Raimer, S., Lawrence, I., Leung, D., Hanifin, J. A randomized vehicle controlled trial of pimecrolimus ointment for treatment of atopic dermatitis in children. *Allergy and Clinical Immunology*. 102(4 Pt 1):637-44,1998. **(Multicenter, randomized double-blind controlled trial; 180 patients)**
46. Schachner, L., Lamerson, C., Sheehan, M., Boguniewicz, M., Mosser, J., Raimer, S., Shull, T., Jaracz, E. Pimecrolimus ointment 0.03% is safe and effective for the treatment of mild to moderate atopic dermatitis in pediatric patients: results from a randomized, double-blind, vehicle controlled study.

- Pediatrics. 116(3):e334-42, 2005. **(Multicenter, randomized double-blind controlled trial; 317 patients)**
47. Kaufmann, R., Folster-Holst, R., Hoyer, P., Thaci, D., Löffler, H., Staab, D., Brautigam, M. Onset of action of pimecrolimus cream 1% in the treatment of atopic infants. *Journal of Allergy and Clinical Immunology*. 114(5):1183-8, 2004. **(Multicenter, randomized double-blind controlled trial; 195 patients)**
48. Kwitkowski, V., Demko, S. Infectious disease emergencies in primary care. *Lippincott's Primary Care practice*. 3(1):108-25, 1999. **(Review Article)**
49. Vincent, J., Demers, D., Bass, J. Infectious exanthems and unusual infections. *Adolescent Medicine State of the Art Reviews*. 11(2):327-58, 2000. **(Review Article)**
50. Demicheli, V., Jefferson, T., Rivetti, A., Price, D. Vaccines for measles, mumps, and rubella in children. *Cochrane Database of Systematic Reviews*. (4):CD004407, 2005. **(Meta-Analysis, systematic review; 139 articles)**
51. Anders, J., Jacobson, R., Poland, G., Jacobsen, S., Wollan, P. Secondary failure rates of measles vaccines: a meta-analysis of published studies. *Pediatric Infectious Disease Journal*. 15(1):62-6, 1996. **(Meta-Analysis, systematic review; 125 articles)**
52. Freeman, T., Stewart, M., Turner, L. Illness after measles-mumps-rubella vaccination. *Canadian Medical Association Journal*. 149(11):1669-74, 1993. **(Prospective randomized controlled clinical trial; 376 patients)**
53. Ferraz, C., Cunha, F., Mota, T., Cavalho, J., Simoes, J., Aparicio, J. Acute respiratory distress syndrome in a child with human parvovirus B19. *Pediatric Infectious Disease Journal*. 24(11):1009-10, 2005. **(Case report; 1 patient)**
54. Kellermayer, R., Faden, H., Grossi, M. Clinical presentation of parvovirus B19 infection in children with aplastic crisis. *Pediatric Infectious Disease Journal*. 22(12):1100-1, 2003. **(Retrospective chart review; 22 patients)**
55. Johnson, L., Pasumathy, A., Saravolatz, D. Parvovirus B19 infection presenting with necrotizing lymphadenitis. *American Journal of Medicine*. 114(4):340-1, 2003. **(Case report; 1 patient)**
56. Ohtomo, Y., Kawamura, R., Kaneko, K., Yamashiro, Y., Kivokawa, N., Taguchi, T., Mimori, K., Fujimoto, J. Nephrotic syndrome associated with human parvovirus B19 infection. *Pediatric Nephrology*. 18(3):280-2, 2003. **(Case report; 1 patient)**
57. Hida, M., Shimamura, Y., Ueno, E., Watanabe, J. Childhood idiopathic thrombocytopenic purpura associated with human parvovirus B19 infection. *Pediatrics International*. 42(6):708-10, 2000. **(Case report; 5 patient)**
58. Moore, T. parvovirus associated arthritis. *Current Opinion in Rheumatology*. 12(4):289-94, 2000. **(Review Article)**
59. Cherry, J. Parvovirus infections in children and adults. *Advances in Pediatrics*. 46:245-69, 1999. **(Review Article)**
60. Minohara, Y., Koitabashi, Y., Kato, T., Nakajima, N., Murakami, H., Masaki, H., Ishiko, H. A case of Guillain-Barre syndrome associated with human parvovirus B19 infection. *Journal of Infection*. 36(3):327-8, 1998. **(Case report; 1 patient)**
61. Wyndham, M. Parvovirus. *Practitioner*. 240(1567):606, 1996. **(Review Article)**
62. Yildirmak, Y., Kemahli, S., Akar, N., Uysal, Z., Cin, S., Arcasoy, A. A case of severe thrombocytopenia due to parvovirus B19 virus. *Pediatric Hematology & Oncology*. 13(2):183-5, 1996. **(Case report; 1 patient)**
63. Rao, S., Desai, N., Miller, S. B19 parvovirus infection and transient aplastic crisis in a child with sickle cell anemia. *Journal of Hematology & Oncology*. 18(2):175-7, 1996. **(Case report; 1 patient)**
64. Okumura, A., Ichikawa, T. Aseptic meningitis caused by human parvovirus B19. *Archives of Diseases in Childhood*. 68(6):784-5, 1993. **(Case report; 1 patient)**
65. Lopreiato, J., Katona, I. Parvovirus B19-induced chronic arthropathy in a child. *Clinical Pediatrics*. 32(5):305-7, 1993. **(Case reports; 6 patients)**
66. Watanabe, T., Satoh, M., Oda, Y. Human parvovirus B19 encephalopathy. *Archives of Diseases in Childhood*. 70(1):71, 1994. **(Case reports; 3 patients)**
67. Tsuda, H., Maeda, Y., Nakagawa, K. Parvovirus B19-related lymphadenopathy. *British Journal of Hematology*. 85(3):631-2, 1993. **(Prospective study; 13 patients)**
68. Frickhofen, N., Chen, Z., Young, N., Cohen, B., Heimpe, H., Abkowitz, J. Parvovirus B19 as a cause of acquired chronic pure red cell aplasia. *British Journal of Hematology*. 87(4):818-24, 1994. **(Retrospective analysis; 57 patients)**
69. Pagliuca, A., Hussain, M., Layton, D. Human parvovirus infection in sickle cell disease. *Lancet*. 342(8862):49, 1993. **(Letter)**
70. Murray, J., Kelley, P., Hogrefe, W., McClain, K. Childhood idiopathic thrombocytopenic purpura: association with human parvovirus B19 infection. *American Journal of Hematology & Oncology*. 16(4):314-9, 1994. **(Prospective controlled study; 35 patients)**
71. Berry, P., Gray, E., Porter, H., Burton, P. Parvovirus infection of the human fetus and newborn. *Seminars in Diagnostic Pathology*. 9(1):4-12, 1992. **(Review Article)**
72. Yoto, Y., Kudoh, T., Haseyama, L., Suzuki, N., Chiba, S. Human parvovirus B19 infection associated with acute hepatitis. *Lancet*. 347(9005):868-9, 1996. **(Retrospective study; 773 patients)**
73. Razozzini, M., Melton, L., Kurland, L. Population based study of herpes zoster and its sequelae. *Medicine*. 61:310, 1982. **(Retrospective study; 590 patients)**
74. Baba, K., Yabuuchi, H., Takahashi, M. Increased incidence of herpes zoster virus during infancy: Community based follow-up study. *Journal of Pediatrics*. 108:372, 1986. **(Prospective clinical trial; 849 patients)**
75. Klassen, T., Hartling, L., Wiebe, N., Belseck, E. Acyclovir for treating varicella in otherwise healthy children and adolescents. *Cochrane Database of Systematic Reviews*. (4):CD002980, 2005. **(Systematic Review)**
76. Rooney, J., Straus, S., Mannix, M., Wohlenberg, C., Alling, D., Dumois, J., Notkins, A. Oral acyclovir to suppress frequently recurrent herpes labialis: a double blind, placebo-controlled trial. *Annals of Internal Medicine*. 118(4):268-72, 1993. **(Randomized controlled clinical trial; 56 patients)**
77. Amir, J., Harel, L., Smetana, Z., Varsano, I. Treatment of herpes simplex gingivostomatitis with acyclovir in children: a randomized double blind, placebo-controlled study. *British Medical Journal*. 314(7097):1800-3, 1997. **(Randomized double-blind controlled clinical trial; 72 patients)**
78. Hansen, R. Staphylococcal scalded skin syndrome, toxic shock syndrome, and Kawasaki disease. *Pediatric Clinics of North America*. 30(3):533-44, 1983. **(Review Article)**
79. Resnick, S. Staphylococcal toxin-mediated syndromes in childhood. *Seminars in Dermatology*. 11(1):11-8, 1992. **(Review Article)**
80. Andrews, M., Parent, E., Barry, M., Parsonnet, J. Recurrent nonmenstrual toxic shock syndrome: clinical manifestations, diagnosis, and treatment. *Clinical Infectious Diseases*. 32(10):1470-9, 2001. **(Case reports; 3 patients)**
81. Sargaves, R. Menstrual toxic shock syndrome. *American pharmacy*. NS35(8):12-7, 1995. **(Review Article)**
82. Chuang, Y., Huang, Y., Lin, T. Toxic shock syndrome in children: epidemiology, pathogenesis, and management. *Pediatric Drugs*. 7(1):11-25, 2005. **(Review Article)**
83. Findlay, R., Odom, R. Toxic shock syndrome. *International Journal of Dermatology*. 21(3):117-21, 1982. **(Review Article)**
84. Tofte, R., Williams, D. Toxic shock syndrome. *Postgraduate Medicine*. 73(1):275-80, 285-8, 1983. **(Review Article)**
85. Chesney, P., Bergdoll, M., Davis, J., Vergeront, J. The disease spectrum, epidemiology, and etiology of toxic shock syndrome. *Annual Review of Microbiology*. 38:315-38, 1984. **(Review Article)**
86. Friedell, S., Mercer, L. Nonmenstrual toxic shock syndrome. *Obstetrical and Gynecological Survey*. 41(6):336-41, 1986. **(Review Article)**
87. Greenman, R., Immerman, R. Toxic shock syndrome. What have we learned? *Postgraduate Medicine*. 81(4):147-8, 153-4, 157-60, 1987. **(Review Article)**
88. Egan, W., Clark, W. The toxic shock syndrome in a burn victim. *Burns, Including Thermal Injury*. 14(2):135-8, 1988. **(Case report; 1 patient)**

89. Arbuthnott, J. Toxic shock syndrome: a multisystem conundrum. *Microbiological Sciences*. 5(1):13-6,1988. **(Review Article)**
90. Resnick, S. Toxic shock syndrome: recent developments in pathogenesis. *Journal of Pediatrics*. 116(3):321-8,1990. **(Review Article)**
91. Floret, D., Stamm, D., Cochat, P., Delmas, P., Kohler, W. Streptococcal toxic shock syndrome in children. *Intensive Care Medicine*. 18(3):175-6,1992. **(Review Article)**
92. Davies, H., Matlow, A., Scriver, S., Schlievert, P., Lovgren, M., Talbot, J., Low, D. Apparent lower rates of streptococcal toxic shock syndrome and lower mortality in children with invasive group A streptococcal infections compared with adults. *Pediatric Infectious Disease Journal*. 13(1):49-56,1994. **(Review Article)**
93. Stausbaugh, L. Toxic shock syndrome: Are you recognizing its changing presentations? *Postgraduate Medicine*. 94(6):107-18,1993. **(Review Article)**
94. McAllister, R., Mercer, N., Morgan, B., Sanders, R. Early diagnosis of staphylococcal toxemia in burned children. *Burns*. 19(1):22-5,1993. **(Case reports; 6 patients)**
95. Tanner, M., Liljenquist, J. Toxic Shock Syndrome from staph aureus infection at insulin infusion pump site. *Journal of the American Medical Association*. 259:394-5,1988.
96. Solomon, R., Truman, T., Murray, D. Toxic Shock Syndrome as a complication of bacterial tracheitis. *Pediatric Infectious Disease Journal*. 4:298-9,1983. **(Case report; 1 patient)**
97. Bradley, J., Schlievert, P., Sample, T. Streptococcal toxic shock-like syndrome as a complication of varicella. *Pediatric Infectious Disease Journal*. 10:77,1991. **(Case report; 1 patient)**
98. Cheneaud, M., Leclerc, F., Martinot, A. Bacterial croup and toxic shock syndrome. *European Journal of Pediatrics*. 145:306-7,1986. **(Case report; 1 patient)**
99. Edward-Jones, V., Shawcross, S. Toxic shock syndrome in the burned patient. *British journal of Biomedical Science*. 54(2):110-7,1997. **(Review Article)**
100. Reingold, A. Toxic Shock in the United States of America. *Postgraduate Medical Journal*. 61(1):23-4, 1985. **Review Article.**
101. George, A., Rubin, G. A systematic review and meta-analysis of treatments for impetigo. *British Journal of General Practice*. 53(491):480-7,2003. **(Meta-analysis review; 16 studies)**
102. Swinger, G., Fransman, D., Hussey, G. Conjugate vaccines for preventing *Haemophilus influenzae* type b infections. *Cochrane Database of Systematic Reviews*. (4):CD001729, 2003. **(Systematic Review)**
103. Ginsburg, C. *Haemophilus influenza* type B buccal cellulitis. *Journal of the American Academy of Dermatology*. 4(6):661-4,1981.
104. Eskola, J., Kayhty, H., Takala, A., Peltola, H., Ronnberg, P., Kela, E., Pekkanen, E., McVerry, P., Makela, P. A randomized prospective field trial of conjugate vaccine in the protection of infants and young children against invasive *Haemophilus influenzae* type b disease. *New England Journal of medicine*. 323(20):1381-7,1990. **(randomized, prospective trial; 114,000 infants and young children)**
105. Fischer, P., Uttenreuther-Fischer, M., Naoe, S., Gaedicke, G. Kawasaki disease: update on diagnosis, treatment, and a still controversial etiology. *Pediatric Hematology & Oncology*. 13(6):487-501,1996. **(Review Article)**
106. Oates-Whitehead, R., Baumer, J., Haines, L., Love, S., Maconochie, I., Gupta, A., Roman, K., Dua, J., Flynn, I. Intravenous immunoglobulin for the treatment of Kawasaki disease in children. *Cochrane Database of Systematic Reviews*. (4):CD004000, 2003. **(Systematic Review)**
107. Sato, N., Sagimura, T., Akagi, T., Yamakawa, R., Hashino, K., Eto, G., Iemura, M., Ishii, M., Kato, H. Selective high dose gamma globulin treatment in Kawasaki disease: assessment of clinical aspects and cost effectiveness. *Pediatrics International*. 41(1):1-7,1999. **(Randomized, controlled trial; 203 patients)**
108. Barron, K., Murphy, D., Silverman, E., Ruttenberg, H., Wright, G., Franklin, W., Goldberg, S., Higashino, S., Cox, D., Lee, M. Treatment of Kawasaki syndrome: a comparison of two dosage regimens of intravenously administered immune globulin. *Journal of Pediatrics*. 117(4):638-44,1990. **(Randomized, multicenter clinical trial; 44 patients)**
109. Ogino, H., Ogawa, M., Harima, Y., Kono, S., Ohkuni, H., Nishida, M., Kobayashi, Y., Yabuuchi, H. Clinical evaluation of gamma globulin preparations for the treatment of Kawasaki disease. *Progress in Clinical & Biological Research*. 250:555-6,1987. **(Randomized, multicenter controlled clinical trial; 92 patients)**
110. Nagashima, M., Matsushima, M., Matsuo, H., Ogawa, A., Okumura, N. High dose gamma globulin therapy for Kawasaki disease. *Journal of Pediatrics*. 110(5):710-2,1987. **(Randomized, controlled trial; 136 patients)**
111. Woodley, D., Saurat, J. The burrow ink test and the scabies mite. *Journal of the American Academy of Dermatology*. 4(6):715-22, 1981.
112. Franz, T., Lehman, P., Franz, S. Comparative percutaneous absorption of lindane and permethrin. *Archives of Dermatology*. 132:901-5,1996. **(Comparison Study)**
113. Rasmussen, J. The problem of lindane. *Journal of the American Academy of Dermatology*. 5:507-16,1981. **(Review Article)**
114. Taplin, D., Meinking, T., Porcelain, S., Castillero, P., Chen, J. Permethrin 5% dermal cream: a new treatment for scabies. *Journal of the American Academy of Dermatology*. 15(5 part 1):995-1001, 1986. **Randomized control trial.**
115. Schultz, M., Gomez, M., Hansen, R., Miller, J., Menter, A., Rogers, P., Judson, F., Mertz, G., Handsfield, H. Comparative study of 5% permethrin cream and 1% lindane lotion for the treatment of scabies. *Archives of Dermatology*. 126(2):167-70, 1990. **Randomized clinical trial.**
116. Illig, L., Weidner, F., Hunderiker, M. Congenital nevi less than or equal to 10 cm as precursors to melanoma: 52 cases, a review, and a new conception. *Archives of Dermatology*. 121:1274-81,1985. **(Prospective clinical trial; 52 patients)**
117. Orlow, S., Paller, A. Cimetidine treatment for multiple viral warts in children. *Journal of the American Academy of Dermatology*. 28:794-96,1993. **(Case reports; 3 patients)**
118. Steere, A., Coburn, J., Glickstein, L. The emergence of Lyme Disease. *Journal of Clinical Investigation*. 113(8):1093-1101,2004. **Review Article.**
119. Couch, P., Johnson, C. Prevention of Lyme disease. *American Journal of Hospital Pharmacy*. 49(5):1164-73,1992. **(Review Article)**
120. Young, G., Evans, S. Safety and efficacy of DEET and permethrin in the prevention of arthropod attack. *Military medicine*. 163(5):324-30,1998. **(Review Article)**
121. Fradin, M. Mosquitoes and mosquito repellents: a clinician's guide. *Annals of Internal Medicine*. 128(11):931-40,1998. **(Review Article)**
122. Goodyer, L., Behrens, R. Short report: The safety and toxicity of insect repellents. *American Journal of Tropical Medicine and Hygiene*. 59(2):323-4,1998. **(Review Article)**
123. Sudakin, D., Trevathan, W. DEET: a review and update of safety and risk in the general population. *Journal of Toxicology*. 41(6):831-9,2003. **(Review Article)**
124. Buka, R. Sunscreen and insect repellents. *Current Opinion in Pediatrics*. 16(4):378-84,2004. **(Review Article)**
125. Roberts, J., Reigart, J. Does anything beat DEET? *Pediatric Annals*. 33(7):443-53,2004. **(Review Article)**
126. Flake, Z., Hinojosa, J., Brown, M., Crawford, P. Clinical inquiries. Is DEET safe for children? *Journal of Family Practice*. 54(5):468-9,2005. **(Review Article)**
127. Osimitz, T., Murphy, J. Neurological effects associated with the use of the insect repellent DEET. *Journal of Toxicology*. 35(5):435-41,1997. **(Review Article)**
128. Mafong, E., Kaplan, L. Insect repellents: What really works? *Postgraduate Medicine*. 102(2):63-74,1997. **(Review Article)**
129. Brown, M., Hebert, A. Insect repellents: an overview. *Journal of the American Academy of Dermatology*. 36(2 Pt 1):243-9,1997. **(Review Article)**
130. Robbins, P., Cherniak, M. Review of the biodistribution and toxicity of the insect repellent DEET. *Journal of Toxicology & Environmental Health*. 18(4):503-25,1986. **(Review Article)**

131. Arndt, K., Jick, H. Rates of cutaneous reactions to drugs. A report from the Boston Collaborative Drug Surveillance program. *Journal of the American Medical Association*. 235(9):918-23, 1976.
132. Watson, N., Weiss, E., Harter, P. Famotidine in the treatment of acute urticaria. *Clinical and Experimental Dermatology*. 25(3):186-9, 2000. **(Prospective, double blind, controlled trial; 25 patients)**
133. Moscati, R., Moore, G. Comparison of cimetidine and diphenhydramine in the treatment of acute urticaria. *Annals of Emergency Medicine*. 19(1):12-5, 1990. **(Randomized, prospective, double-blind clinical trial; 93 patients)**
134. Foulds, I., Mackie, R. A double blind trial of the H2 receptor antagonist cimetidine, and the H1 receptor antagonist promethazine hydrochloride in the treatment of atopic dermatitis. *Clinical Allergy*. 11(4):319-23, 1981. **(Randomized, double-blind clinical trial; 20 patients)**
135. Kroonen, L. Erythema multiforme: case report and discussion. *Journal of the American Board of Family Practice*. 11(1):63-5, 1998. **(Case reports; 4 patients)**
136. Huff, J., Weston, W. Recurrent erythema multiforme. *medicine*. 68:133, 1989. **(Prospective clinical trial; 22 patients)**
137. Werchniak, A., Schwartzberger, K. Poison ivy: an underreported cause of erythema multiforme. *Journal of the American Academy of Dermatology*. 51(5suppl):S159-60, 2004. **(Case reports; 4 patients)**
138. Cohen, L., Cohen, J. Erythema multiforme associated with contact dermatitis to poison ivy: three cases and a review of the literature. *Cutis*. 62(3):139-42, 1998. **(Case reports; 3 patients)**
139. Renfro, L., Grant-Kels, J., Feder, H., Daman, L. Controversy: are systemic steroids indicated in the treatment of erythema multiforme? *pediatric Dermatology*. 6(1):43-50, 1989. **(Case reports; 3 patients)**
140. Ginsburg, C. Stevens-Johnson syndrome in children. *Pediatric Infectious Disease*. 1:155, 1982. **(Retrospective controlled clinical trial; 51 patients)**
141. Straussberg, R., Harel, L., Ben-Amitai, D., Cohen, D., Amir, J. Carbamazepine-induced Stevens-Johnson syndrome treated with IV steroids and IVIG. *pediatric Neurology*. 22(3):231-3, 2000. **(Case report; 1 patient)**
142. Martinez, A., Atherton, D. High dose systemic corticosteroids can arrest recurrences of severe mucocutaneous erythema multiforme. *pediatric Dermatology*. 17(2):87-90, 2000. **(Case reports; 2 patients)**
143. Kakourou, T., Klontza, D., Soteropoulou, F., Kattamis, C. Corticosteroid treatment of erythema multiforme major (Stevens-Johnson syndrome) in children. *European Journal of Pediatrics*. 156(2):90-3, 1997. **(Prospective clinical trial; 16 children)**
144. Wright, S. Treatment of erythema multiforme major with systemic corticosteroids. *British Journal of Dermatology*. 124(6):612-3, 1991. **(Correspondance)**
145. Esterly, N. Special symposium: Corticosteroids for erythema multiforme? *Pediatric Dermatology*. 6:229, 1989. **(Symposium)**
146. Cohen, B., Honig, P., Androphy, E. Anogenital warts in children: clinical and virologic evaluation for sexual abuse. *Archive of Dermatology*. 126:1575-80, 1990. **(Prospective clinical trial; 73 patients)**
147. American Academy of Dermatology task Force on Pediatric Dermatology: Genital warts and sexual abuse in children. *Journal of the American Academy of Dermatology*. 11:529, 1984. **(task Force on Pediatric Dermatology)**
148. McCoy, C., Applebaum, H., Besser, A. Condylomata accuminata: an unusual presentation of child abuse. *Journal of Pediatric Surgery*. 17:505, 1982. **(Case reports; 4 patients)**
149. Roch, B., Naghashfat, Z., Barnett, N. Genital tract papilloma virus infection in children. *Archive of Dermatology*. 122:1129, 1986. **(Case reports; 5 patients)**
150. Schachner, L., Hankin, D. Assessing child abuse in childhood condylomata accuminata. *Journal of the American Academy of Dermatology*. 12:157, 1985. **(Review Article)**
151. Seidel, J., Zonana, J., Totten, E. Condylomata accuminata as a sign of sexual abuse in children. *Journal of Pediatrics*. 95:553, 1979. **(Case reports; 5 patients)**
152. White, S., Luda, F., Ingram, D. Sexually transmitted diseases in sexually abused children. *Pediatrics*. 72:16, 1983. **(Retrospective clinical study; 409 patients)**
153. Obalik, S., Jablonski, S., Favre, M. Condylomata accuminata in children: frequent association with human papilloma virus responsible for cutaneous warts. *Journal of the American Academy of Dermatology*. 23:205, 1990. **(Case reports; 32 patients)**
154. Dejong, A., Weiss, J., Brent, R. Condylomata accuminata in children. *American Journal of Diseases of Children*. 136:704, 1982. **(Case reports; 34 patients)**
155. Padel, A., Venning, V., Evans, M. Human papilloma virus in anogenital warts in children: typing by in situ hybridization. *British Medical Journal*. 300:1491, 1990. **(Multicenter, prospective study; 17 patients)**
156. Litt, J. Don't excise - exorcise. Treatment for subungual and periungual warts. *Cutis*. 22(6):673-6, 1978. **Case report.**
157. Lorentzen, M., Pers, M., Bretteville-Jensen, G. The incidence of malignant transformation of giant pigmented nevi, *Scandinavian Journal of Plastic reconstructive Surgery*. 11:163-67, 1977. **(Retrospective clinical study; 151 patients)**
158. Quaba, A., Wallace, A. The incidence of malignant melanoma (0 to 15 years) arising in "large" congenital nevocellular nevi. *Plastic Reconstructive Surgery*. 78:174-9, 1986. **(Observational study; 39 patients)**
159. Clark, W., Reiner, R., Greene, M. Origin of familial malignant melanoma from heritable melanocytic lesions. *Archive of dermatology*. 114:732-8, 1978. **(Prospective study; 37 patients)**
160. Rhodes, A., Wood, W., Sober, A. Nonepidermal origin of malignant melanoma associated with giant congenital nevocellular nevi. *Plastic reconstructive Surgery*. 67:782-90, 1981. **(Case report; 1 patient)**
161. Skov-Jensen, T., Hastrup, J., Lambrechtsen, E. Malignant melanoma in children. *Cancer*, 19:620-6, 1966. **(Case report; 2 patients)**
162. Truzak, D., Rowland, W., Hu, F. Metastatic malignant melanoma in prepubertal children. *Pediatrics*. 55:191-204, 1975. **(Review Article)**
163. Rhodes, A., Melski, J. Small congenital nevocellular nevi and the risk of cutaneous melanoma. *Journal of Pediatrics*. 100:219-24, 1982. **(Prospective study; 134 patients)**
164. Rhodes, A. Pigmented birthmarks and precursor melanocytic lesions of cutaneous melanoma identifiable in children. *Pediatric Clinics of North America*. 30:435-63, 1983. **(Symposium)**
165. Holly, E., Kelly, J., Shpall, S. Number of melanocytic nevi as a major risk factor for malignant melanoma. *Journal of the American Academy of Dermatology*. 17:459-68, 1987. **(Prospective, case-controlled trial; 260 patients)**
166. Masri, G., Clark, W., Dupont, G. Screening and surveillance of patients at high risk for malignant melanoma results in detection of earlier disease. *Journal of the American Academy of Dermatology*. 22:1042-8, 1990. **(Prospective study; 555 patients)**
167. Anaise, D., Steinitz, R., BentHur, N. Solar radiation: a possible etiologic factor in malignant melanoma in Israel. *Cancer*. 42:299-304, 1978. **(Retrospective clinical trial; 966 patients)**
168. Sober, A., Lew, R., Cook, N., Marvell, R., Fitzpatrick, T. Sun exposure habits in patients with cutaneous melanoma: A case control study. *Journal of Dermatologic Surgery and Oncology*. 9(12):981-6, 1983.
169. MacKie, R., Freudenberger, T., Aitchison, T. Personal risk factor chart for cutaneous melanoma. *Lancet*. 2:487-90, 1989. **(Case-controlled trial; 371 patients)**
170. Dennis, L., Beane, F., VanBeek, L., Marta, J. Sunscreen use and the risk for melanoma: a quantitative review. *Annals of Internal Medicine*. 139(12):966-78, 2003. **(Quantitative review of 18 studies published from 1966 to 2003)**
171. Huncharek, M., Kupelnick, B. Use of topical sunscreen and the risk for melanoma: a meta-analysis of 9067 patients from 11 case-control studies. *American Journal of Public Health*. 92(7):1173-7, 2002. **(Pooled observational study)**

CME Questions

17. Which statement regarding the penetration of corticosteroids placed on intact skin is true?
- Topical agent vehicle (petrolatum vs. hydrophilic cream) may affect systemic absorption/potency
 - Non-occlusive dressing may affect systemic absorption/potency
 - Application on the palms/soles increases penetration of corticosteroids
 - Systemic absorption of topical corticosteroids has little to do with the age of the child
18. An example of a low potency topical steroid is:
- 0.1% valisone
 - 0.2% westcort
 - 0.05% desonide
 - 0.5% aristocort
19. Acute management of atopic dermatitis includes:
- Topical steroids
 - Removal of known irritants
 - Skin moisturizers
 - All the above
20. A study by Reitamo comparing 1% hydrocortisone with pimecrolimus (0.03% and 0.1%) showed that pimecrolimus was:
- Equally effective
 - Less effective
 - Ineffective
 - More effective
21. Seborrheic dermatitis may be differentiated from atopic dermatitis by:
- Milder pruritis in seborrheic dermatitis
 - Onset during infancy in seborrheic dermatitis
 - Diaper area involvement in seborrheic dermatitis
 - Scalp and forehead involvement in seborrheic dermatitis
 - All of the above
22. According to Fisher, the most common cause of contact dermatitis is:
- Rhus plants
 - Nickel
 - Rubber
 - Cosmetics
23. Tzanck smears may be helpful in the diagnosis of:
- Herpes infection
 - Scabies
 - Fungal infection
 - Staph infection
24. Atopic dermatitis typically affects what area in infants?
- Flexural surface of the extremities
 - Hands and feet
 - Face
 - Antecubital and popliteal fossae
25. The following infections are manifested by an exanthem *EXCEPT*:
- Roseola
 - Scarlet fever
 - Varicella
 - Fifth's disease
 - Rubella
26. Features which may help to differentiate rubella from rubeola include:
- Patients with rubella are often less toxic / febrile
 - Leukopenia
 - Rubella may prove harmful to the unborn fetus
 - Non-productive cough with viral URI like symptoms (rhinorrhea)
 - A and C
27. A positive "Nikolsky" sign may be manifested in which infection?
- Rubella
 - Epstein-Barr Viral infection
 - Staphylococcal Scalded Skin Syndrome
 - Toxic Shock syndrome
 - Enteroviral infection
28. The following may be caused by staphylococcus *EXCEPT*:
- Scalded skin syndrome
 - Toxic shock syndrome
 - Cellulitis
 - Impetigo
 - Scarlet Fever
29. Features which are important to identify before considering a clinical diagnosis of Toxic Shock Syndrome include:
- High grade fever often greater than 39°C
 - Severe myalgia often with CPK elevation
 - Renal abnormalities often with elevated BUN
 - Hypotension
 - All the above
30. A child with a febrile illness placed on amoxicillin presents to you with a generalized truncal rash. Which illness should be included on your differential diagnosis?
- Epstein-Barr virus
 - Rubella

- c. Varicella
- d. Coxsackie
- e. Scarlet fever

31. A child with sickle cell anemia would be at particular risk if he was diagnosed with:

- a. Fifth's disease
- b. Rubella
- c. Varicella
- d. Roseola
- e. Scarlet fever

32. Acyclovir may be considered for which of the following infections?

- a. Roseola
- b. Varicella
- c. Enteroviral infection
- d. Herpes Simplex
- e. B and D

Class Of Evidence Definitions

Each action in the clinical pathways section of *Pediatric Emergency Medicine Practice* receives a score based on the following definitions.

Class I

- Always acceptable, safe
- Definitely useful
- Proven in both efficacy and effectiveness

- levels of evidence
- Case series, animal studies, consensus panels
- Occasionally positive results

Indeterminate

- Continuing area of research
- No recommendations until further research

Level of Evidence:

- One or more large prospective studies are present (with rare exceptions)
- High-quality meta-analyses
- Study results consistently positive and compelling

Class II

- Safe, acceptable
- Probably useful

- Level of Evidence:
- Evidence not available
- Higher studies in progress
- Results inconsistent, contradictory
- Results not compelling

Level of Evidence:

- Generally higher levels of evidence
- Non-randomized or retrospective studies: historic, cohort, or case-control studies
- Less robust RCTs
- Results consistently positive

Class III

- May be acceptable
- Possibly useful
- Considered optional or alternative treatments

Level of Evidence:

- Generally lower or intermediate

Significantly modified from: The Emergency Cardiovascular Care Committees of the American Heart Association and representatives from the resuscitation councils of ILCOR: How to Develop Evidence-Based Guidelines for Emergency Cardiac Care: Quality of Evidence and Classes of Recommendations; also: Anonymous. Guidelines for cardiopulmonary resuscitation and emergency cardiac care. Emergency Cardiac Care Committee and Subcommittees, American Heart Association. Part IX. Ensuring effectiveness of community-wide emergency cardiac care. JAMA 1992;268(16):2289-2295.

Physician CME Information

Accreditation: This activity has been planned and implemented in accordance with the Essentials and Standards of the Accreditation Council for Continuing Medical Education (ACCME) through the joint sponsorship of Mount Sinai School of Medicine and *Pediatric Emergency Medicine Practice*. The Mount Sinai School of Medicine is accredited by the ACCME to provide continuing medical education for physicians.

Credit Designation: The Mount Sinai School of Medicine designates this educational activity for a maximum of 48 AMA PRA Category 1 Credit(s)[™] per year. Physicians should only claim credit commensurate with the extent of their participation in the activity.

Credit may be obtained by reading each issue and completing the printed post-tests administered in December and June or online single-issue post-tests administered at EBMedicine.net.

Target Audience: This enduring material is designed for emergency medicine physicians.

Needs Assessment: The need for this educational activity was determined by a survey of medical staff, including the editorial board of this publication; review of morbidity and mortality data from the CDC, AHA, NCHS, and ACEP; and evaluation of prior activities for emergency physicians.

Date of Original Release: This issue of *Pediatric Emergency Medicine Practice* was published March 1, 2007. This activity is eligible for CME credit through March 1, 2010. The latest review of this material was February 1, 2007.

Discussion of Investigational Information: As part of the newsletter, faculty may be presenting investigational information about pharmaceutical products that is outside Food and Drug Administration approved labeling. Information presented as part of this activity is intended solely as continuing medical education and is not intended to promote off-label use of any pharmaceutical product. Disclosure of Off-Label Usage: This issue of *Pediatric Emergency Medicine Practice* discusses no off-label use of any pharmaceutical product.

Faculty Disclosure: It is the policy of Mount Sinai School of Medicine to ensure objectivity, balance, independence, transparency, and scientific rigor in all CME-sponsored educational activities. All faculty participating in the planning or implementation of a sponsored activity are expected to disclose to the audience any relevant financial relationships and to assist in resolving any conflict of interest that may arise from the relationship. Presenters must also make a meaningful disclosure to the audience of their discussions of unlabeled or unapproved drugs or devices.

In compliance with all ACCME Essentials, Standards, and Guidelines, all faculty for this CME activity were asked to complete a full disclosure statement. The information received is as follows: Dr. Lampell, Dr. Mace, and Dr. Whiteman report no significant financial interest or other relationship with the manufacturer(s) of any commercial product(s) discussed in this educational presentation.

For further information, please see The Mount Sinai School of Medicine website at www.mssm.edu/cme.

ACEP Accreditation: *Pediatric Emergency Medicine Practice* is also approved by the American College of Emergency Physicians for 48 hours of ACEP Category 1 credit per annual subscription.

AAP Accreditation: This continuing medical education activity has been reviewed by the American Academy of Pediatrics and is acceptable for up to 48 AAP credits. These credits can be applied toward the AAP CME/CPD Award available to Fellows and Candidate Fellows of the American Academy of Pediatrics.

Earning Credit: Two Convenient Methods

• **Print Subscription Semester Program:** Paid subscribers with current and valid licenses in the United States who read all CME articles during each *Pediatric Emergency Medicine Practice* six-month testing period, complete the post-test and the CME Evaluation Form distributed with the December and June issues, and return it according to the published instructions are eligible for up to 4 hours of CME credit for each issue. You must complete both the post test and CME Evaluation Form to receive credit. Results will be kept confidential. CME certificates will be delivered to each participant scoring higher than 70%.

• **Online Single-Issue Program:** Current, paid subscribers with current and valid licenses in the United States who read this *Pediatric Emergency Medicine Practice* CME article and complete the online post-test and CME Evaluation Form at EBMedicine.net are eligible for up to 4 hours of Category 1 credit toward the AMA Physician's Recognition Award (PRA). You must complete both the post-test and CME Evaluation Form to receive credit. Results will be kept confidential. CME certificates may be printed directly from the Web site to each participant scoring higher than 70%.

***Pediatric Emergency Medicine Practice* is not affiliated with any pharmaceutical firm or medical device manufacturer.**

CEO: Robert Williford **President and Publisher:** Stephanie Williford **Director of Member Services:** Liz Alvarez

Direct all editorial or subscription-related questions to EB Medicine: 1-800-249-5770 • Fax: 1-770-500-1316 • Non-U.S. subscribers, call: 1-678-366-7933

EB Practice, LLC • 305 Windlake Court • Alpharetta, GA 30022

E-mail: ebm@ebmedicine.net • Web Site: EBMedicine.net

Pediatric Emergency Medicine Practice (ISSN Print: 1549-9650, ISSN Online: 1549-9669) is published monthly (12 times per year) by EB Practice, LLC, 305 Windlake Court, Alpharetta, GA 30022. Opinions expressed are not necessarily those of this publication. Mention of products or services does not constitute endorsement. This publication is intended as a general guide and is intended to supplement, rather than substitute, professional judgment. It covers a highly technical and complex subject and should not be used for making specific medical decisions. The materials contained herein are not intended to establish policy, procedure, or standard of care. *Pediatric Emergency Medicine Practice* is a trademark of EB Practice, LLC. Copyright .2006 EB Practice, LLC. All rights reserved. No part of this publication may be reproduced in any format without written consent of EB Practice, LLC. Subscription price: \$299, U.S. funds. (Call for international shipping prices.)