

Diagnosis And Management Of Hand Injuries In The ED

It's a busy Friday night in your ED, and you evaluate a 21-year-old male who has lacerated his flexor tendon on a glass bottle during a bar fight. The on-call orthopedist suggests placing Steri-Strips™ and sending the patient to his clinic early next week. After hanging up the phone, you immediately have misgivings. The other orthopedists usually take the patient to the operating room directly from the ED. You ask yourself, "Should I start antibiotics? Did he really understand me in his post-REM sleep fog? Shouldn't the patient get his tendon repaired tonight, or at least this weekend? How do I splint the finger?" You wonder if you shouldn't call him back, just to be sure....

THE hand is a complex and truly amazing work of anatomy. The bones, muscles, tendons, nerves, and ligaments work in precision to create a masterpiece of functionality and sense. Disrupt just one of these parts, and the entire balance of the hand can be thrown off. Yet our patients often seem determined to do exactly that, and the literature is replete with an unusual and comprehensive list of how these injuries occur: axes, dry cleaner injectors, gunshot wounds, farming mishaps, table saws, boxing, rock climbing — the list goes on and on.

The critical importance of our sense of touch makes hand injuries different from other traumatic injuries. We are constantly receiving sensory input from our hands, relying on that information for our normal day-to-day functioning: We grope for the snooze button in the dark, type on a computer, cut, hammer, throw a softball, caress a lover's face or hold a child's hand without conscious effort. When a traumatic hand injury results in chronic stiffness, pain, and dysfunction, a patient will be constantly reminded of it during nearly every waking minute of the day.

An entire subspecialty of training is dedicated to the hand, yet emergency physicians, general orthopedists, and primary care providers manage the bulk of acute, traumatic hand injuries. The art of managing emergent hand conditions rests in correctly identifying and treating such injuries, which can be difficult at times, due to subtle presentations. A critical step is determining which ones you can appropriately manage, and which need ur-

February 2005

Volume 7, Number 2

Authors

Benjamin Harrison, MD, FACEP

Program Director, Madigan Army Medical Center—University of Washington Emergency Medicine Residency—Tacoma, WA.

Patrick Holland, MD

Clinical Instructor and Medical Student Coordinator, Madigan Army Medical Center—University of Washington Emergency Medicine Residency—Tacoma, WA.

Peer Reviewers

Andrew Perron, MD, FACEP, FACS

Residency Program Director, Department of Emergency Medicine, Maine Medical Center—Portland, ME.

Andy Jagoda, MD, FACEP

Vice-Chair of Academic Affairs, Department of Emergency Medicine; Residency Program Director, Mount Sinai School of Medicine—New York, NY.

CME Objectives

Upon completing this article, you should be able to:

1. Apply basic knowledge of hand anatomy and physiology while examining and managing acute hand injuries;
2. Classify common hand fractures, dislocations, and tendon injuries and their complications;
3. Identify the steps in properly evaluating open hand wounds, considering high-risk situations that require special attention; and
4. Discuss the proper ED management of hand burns, arterial and nerve injury, and high-pressure injection injury to the hand.

Date of original release: February 15, 2005.

Date of most recent review: February 9, 2005.

See "Physician CME Information" on back page.

Editor-in-Chief

Andy Jagoda, MD, FACEP, Vice-Chair of Academic Affairs, Department of Emergency Medicine; Residency Program Director; Director, International Studies Program, Mount Sinai School of Medicine, New York, NY.

Associate Editor

John M. Howell, MD, FACEP, Clinical Professor of Emergency Medicine, George Washington University, Washington, DC; Director of Academic Affairs, INOVA Fairfax Hospital Emergency Department, Emergency Physicians of Northern Virginia.

Editorial Board

William J. Brady, MD, Associate Professor and Vice Chair,

Department of Emergency Medicine, University of Virginia, Charlottesville, VA.

Judith C. Brillman, MD, Professor, Department of Emergency Medicine, The University of New Mexico Health Sciences Center School of Medicine, Albuquerque, NM.

Francis M. Fesmire, MD, FACEP, Director, Heart-Stroke Center, Erlanger Medical Center; Assistant Professor of Medicine, UT College of Medicine, Chattanooga, TN.

Valerio Gai, MD, Professor and Chair, Department of Emergency Medicine, University of Turin, Italy.

Michael J. Gerardi, MD, FAAP, FACEP, Clinical Assistant Professor, Medicine, University of Medicine and Dentistry of New Jersey; Director, Pediatric Emergency Medicine, Children's

Medical Center, Atlantic Health System; Department of Emergency Medicine, Morristown Memorial Hospital.

Michael A. Gibbs, MD, FACEP, Chief, Department of Emergency Medicine, Maine Medical Center, Portland, ME.

Gregory L. Henry, MD, FACEP, CEO, Medical Practice Risk Assessment, Inc., Ann Arbor, MI; Clinical Professor, Department of Emergency Medicine, University of Michigan Medical School, Ann Arbor, MI; Past President, ACEP.

Francis P. Kohrs, MD, MSPH, Lifelong Medical Care, Berkeley, CA.

Keith A. Marill, MD, Emergency Attending, Massachusetts General Hospital; Faculty, Harvard Affiliated Emergency Medicine Residency, Boston, MA.

Michael S. Radeos, MD, MPH, Attending Physician, Department of Emergency Medicine, Lincoln Medical and Mental Health Center, Bronx, NY; Assistant Professor in Emergency Medicine, Weill College of Medicine, Cornell University, New York, NY.

Steven G. Rothrock, MD, FACEP, FAAP, Associate Professor of Emergency Medicine, University of Florida; Orlando Regional Medical Center; Medical Director of Orange County Emergency Medical Service, Orlando, FL.

Robert L. Rogers, MD, FAAEM, Assistant Professor of Surgery and Medicine; Program Director, Combined Emergency Medicine/Internal Medicine Residency, Department of Surgery/Division of Emergency Medicine And Department of Medicine, The University

of Maryland School of Medicine, Baltimore, MD.

Alfred Sacchetti, MD, FACEP, Research Director, Our Lady of Lourdes Medical Center, Camden, NJ; Assistant Clinical Professor of Emergency Medicine, Thomas Jefferson University, Philadelphia, PA.

Corey M. Slovis, MD, FACP, FACEP, Professor of Emergency Medicine and Chairman, Department of Emergency Medicine, Vanderbilt University Medical Center; Medical Director, Metro Nashville EMS, Nashville, TN.

Charles Stewart, MD, FACEP, Colorado Springs, CO.

Thomas E. Terndrup, MD, Professor and Chair, Department of Emergency Medicine, University of Alabama at Birmingham, Birmingham, AL.

gent referral, then providing proper splinting and wound management. This issue of *Emergency Medicine PRACTICE* will provide guidelines that the emergency physician can use to meet these goals.

Critical Appraisal Of The Literature

Overall, the hand injury literature is not evidence-based, but instead relies on tradition. A search of both the National Guideline Clearinghouse (<http://www.guidelines.gov>) and OVID found only 3 evidence-based practice guidelines related to the evaluation and management of hand injuries. These include recommendations for hand imaging by an expert panel of radiologists, a clinical policy on the approach to penetrating extremity trauma by the American College of Emergency Physicians, and a Cochrane systematic review of antibiotic prophylaxis for mammalian bites, all of which are referenced in more detail later in this article. The stronger randomized, controlled studies that exist on hand injuries focus on their operative or rehabilitative aspects and are found in the hand surgery or occupational therapy literature. Even in respected texts on hand surgery, several authors disagree over how to best evaluate and treat a given injury. Emergency medicine-based trials are sparse regarding the ED management of hand injuries, leaving us to rely primarily on “expert opinion.” Recommendations for managing injuries pending specialty consultation (which can be delayed for days or weeks) lack support, and in many instances simply do not exist. Regarding operative management, enough variation in surgical practice exists that makes it wise to refer early and leave definitive decisions to the consultant.

Most practicing emergency physicians have been taught and use sound and reasonable approaches to evaluating hand injuries. Most of these pass “the common sense test” and, until more definitive literature exists, should be considered useful. Expert witnesses most certainly will refer to such recommendations and hold them up as “standard of care,” even if they simply come from textbooks and are not clearly supported by definitive data. Hopefully, with time, we will fill in the knowledge gaps with evidence-based support, but much work remains.

Epidemiology

Hand injuries comprise up to 10% of ED visits and range from simple lacerations or finger sprains to mutilating injuries or amputations.^{1,2} Hand lacerations are the most frequently seen injuries of the hand, yet hand fractures and dislocations account for approximately 20% of fractures in general.^{3,4} The type of injury seen in each decade of life varies; children most commonly are injured at home, with fingertip injuries and burns prevailing.⁵ In 1 study, over half of abused infants had hand fractures — a subtle but important fact to keep in mind when evaluating these injuries in this age group.⁶ Falls are frequently the etiology in the elderly; sports in younger patients, and work-related injuries in middle-aged individuals.⁷ Males are injured

more frequently in almost all age groups.^{5,8} More severe trauma usually results from motor vehicle collisions, farm or industrial machinery, table saws, fireworks, snowblowers, or lawnmowers. These are generally “no-brainers” that require prompt involvement by a hand surgeon.

Fingers are fractured more frequently than metacarpals, with the little finger ray (phalanx and metacarpal) being fractured more often than the other 4 rays.⁴ A British study published in 1990 pointed out that 25% of finger fractures were initially mismanaged, leading the authors to recommend that all such injuries be referred to a hand surgeon; a corollary to this study is the imperative that emergency physicians be facile in recognizing and managing hand injuries.⁹

Missed tendon lacerations are a common cause for litigation, thus driving the need for all emergency physicians to have a basic understanding of the anatomical and functional complexity of hand anatomy. The expense of treating a patient combined with their time lost from workplace productivity may exceed tens of thousands of dollars, as most patients rely heavily on their hands to function optimally on the job.¹⁰

Anatomy And Physiology Of The Hand

No other musculoskeletal system is as multifaceted and complex as the hand, making it impractical for most to memorize and fully understand all the details of hand anatomy and physiology. However, the practicing emergency physician should “have a feel” for the general function of the bones, tendons, joints, vascular supply, and nerves of the hand. Familiarization with these basic tenets makes it possible to identify injuries and recognize both their potential short- and long-term complications.

General Terms

It is best to describe the surfaces of the hand using proper anatomic terminology; not only is it more descriptive, but it will lend credence to conversations with your consultants. The palmar or volar surface is opposite the dorsal surface of the hand, while the surface of each finger or hand that is facing the radius is termed the radial surface. Conversely, the ulnar surface lies on the same side of the ulna in that extremity. Motion of joints is described as flexion, extension, hyperextension, radial deviation, or ulnar deviation. The type of deviation is determined by the direction of the most distal part involved. The fingers, or phalanges, are aptly named index, middle (or long), ring, and little. Each finger has 2 interphalangeal (IP) joints — distal (DIP) and proximal (PIP) — while the thumb has 1 IP joint. The 5 metacarpophalangeal (MP) joints connect the metacarpal (MC) bones to the proximal phalanges. The metacarpals are similarly named as the phalanges, or they may be referred to as MC 1 (thumb) through MC 5 (little finger).

Skeleton

There are 19 bones of each hand (14 phalanges and 5 meta-

carpals). The distal carpals of the wrist, along with the index and middle finger metacarpal, form the fixed and immobile center of the hand.

Blood Supply

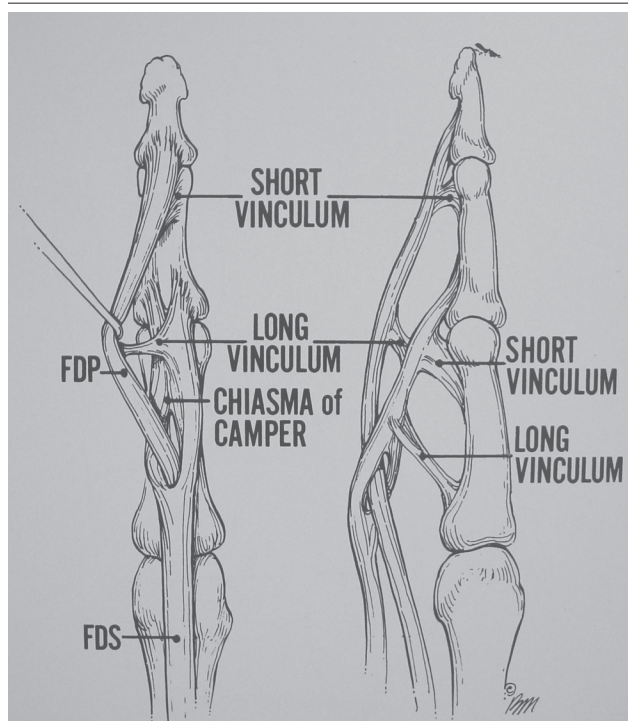
A series of arches and arcades provide dual blood supply to the entire hand and all digits. The radial and ulnar arteries provide the major blood supply to the hand by forming the superficial and deep palmar arches. The common digital arteries are the main branches off the superficial arch, and there are many variations of its branches. The proper digital arteries have multiple transverse arcades of branches in the digits. This system of abundant collaterals in the hand makes it very unlikely that you will encounter clinical problems with disruption of 1 of the 2 main arteries at the wrist or with disruption of a palmar arch.¹¹ Veins generally parallel the deep arterial system.

Synovial Spaces

Synovial fluid provides nourishment to tendons and decreases friction during tendon movement. Extensor tendons have increased resistance to infection because they do not lie within fixed sheaths in the hand, although small sheaths do surround them at the wrist. Flexor

Figure 1. The flexor digitorum profundus.

The flexor digitorum profundus passes through the tails of the flexor digitorum superficialis on the way to its insertion into the distal phalanx.



Used with permission from: Green DP, Hotchkiss RN, Pederson WC, eds. *Operative Hand Surgery*. Vol 1. New York: Churchill Livingstone; 1999:1899. Figure 60-1.

tendon sheaths can act as a pathway for the spread of infection (flexor tenosynovitis), most often from penetrating trauma.

Flexor Tendons

The 12 flexor tendons cross the wrist volarly. The thumb has only 1 flexor tendon, the flexor pollicis longus, which distinguishes it from the other digits. The remaining digits have 2 flexor tendons, the flexor digitorum superficialis (FDS) and the flexor digitorum profundus (FDP). At the base of each proximal phalanx, the FDS bifurcates into 2 slips, allowing the FDP to emerge to a superficial position between the 2 slips (**Figure 1**). The 2 FDS slips insert at the proximal aspect of the middle phalanx, while the FDP inserts at the base of the distal phalanx. Distal to the MP joint, both flexor tendons become enclosed in a fibrous synovial sheath. Regions of thickening form pulleys that prevent bowstringing of the flexor tendons as they cross joints, thus facilitating smooth and efficient flexion. These pulleys are often injured acutely or chronically in the hands of rock climbers, leading to "bowstringing" of the flexor tendon.¹²

Extensor Tendons

The 9 extensor tendons of the hand cross the wrist dorsally and are separated into 6 distinct compartments while passing under the extensor retinaculum. This is the only area where they are encompassed in synovial sheaths. The retinaculum and compartment roofs provide stabilization for the extensor tendons, thus preventing bowstringing of the tendons in extension.

Each extensor mechanism is a complex arrangement of muscle tendon units of the long extensor tendons and the intrinsic system. Because of this complex anatomy, injuries involving the extensor mechanism require meticulous repair.

Prehospital Care

Prehospital care focuses on stabilization of the injury, on hemorrhage and pain control, as well as on the care of amputated parts. The injured extremity should be immobilized and elevated. Hemorrhage control can typically be achieved with direct pressure. In rare instances, patients suffer arterial injuries that can often be difficult to control with direct pressure. Tourniquet use is appropriate to prevent exsanguination or shock when direct pressure of the radial or ulnar artery is unsuccessful. A manual blood pressure cuff applied proximal to the injury and inflated to 250 mm Hg will provide adequate hemostasis during prehospital transport. Prehospital care personnel should use intravenous narcotics for pain relief and anxiolytics when indicated, such as with crush or mangled injuries.

Amputations

Limited research has been done on the care of an amputated digit or hand. Paramedics should try to find *any* amputated digit, wrap it in sterile, saline-soaked gauze,

Table 1. Indications For Digital Replantation.

Single digit amputation between the PIP and DIP

Amputated thumbs

Multiple digit amputations

Any amputation in a child

Mid-palmar amputations

then place it into a plastic bag that is in turn placed into a separate plastic bag containing ice. Cooling an amputated digit close to 40° C will enhance survival; 1 hour of warm ischemia is approximately equal to 6 hours of cold ischemia.¹³ Even if the amputated part is not suitable for replantation, it may be used as a source of donor vessels, skin, or bone. Recommendations for digit replantation are presented in **Table 1**.

ED Evaluation

First and foremost, address the ABCs in any acute traumatic scenario. A mangled, amputated, or crushed hand should not draw attention away from more serious life threats and, unless profusely bleeding, should not take priority in the multitrauma patient.

History

Always obtain a complete history when evaluating patients with hand injuries. EMS personnel or bystanders may be able to offer important historical facts, if the patient is unable to communicate. Was the patient's hand protruding through the window when a vehicle rolled? Were there any gross deformities that were reduced prior to transport? Basic historical details should include: patient's hand dominance, medical history (especially immunocompromising diseases or medications), tetanus status, allergies, smoking status, previous hand injuries or dysfunction, and occupation and hobbies (eg, musician or anything requiring fine motor control). Obtain a history of the mechanism of injury. Crush injuries impart more force and damage to soft tissue than simple blows to the hand, increasing the risk of compartment syndrome and wound infection. Identify the force causing a joint dislocation and in which direction the joint was deformed, if already reduced: This helps diagnosing ligament damage in closed injuries.

Seek details surrounding lacerations or puncture wounds. Did the patient fall on a road covered with gravel? Did glass, tree branches or other material cause the laceration? Causes such as these not only raise the suspicion of foreign bodies in the wound, but also direct the type of imaging used to evaluate the wound for foreign bodies. In a study addressing the question of retained glass, foreign body sensation was a poor predictor of glass foreign body (positive predictive value of only 31%). In

one study, patients who thought that there was no glass in the wound were usually right, but there were still a good number of false negatives (negative predictive value of 89%).¹⁴

Time since injury may help determine whether or not a wound should be closed and the risk for infection. Exposure to contamination (eg, lake water, soil, "dirty" tool or knife, or bites) may also influence clinical decisions involving closure and antibiotic therapy. Determine the position of the hand at the time of injury; this can help locate damaged structures during physical examination that are not visualized in a wound of a hand in the resting position. Pay particular attention to open injuries of the MP joints. Ruling out a "fight-bite" injury (striking of the knuckles against teeth) as the etiology is imperative, as these wounds require a higher level of management than most other hand lacerations.

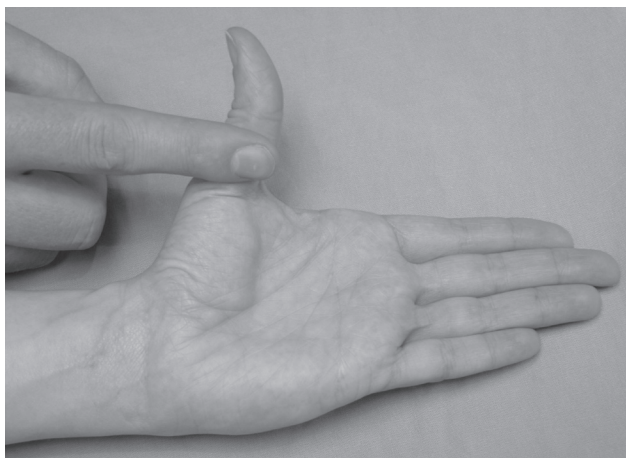
Examination

While providing basic trauma care, obtain hemorrhage control of an open wound or amputation by using direct pressure with gauze and arm/hand elevation. If this fails, as it rarely should, the next step is to place a blood pressure cuff at the distal forearm or wrist. Inflate to 250 mm Hg pressure for 20- to 30-minute periods. Most patients tolerate tourniquets of this duration without significant pain.¹⁵ Avoid using a Kelly clamp and thereby crushing arteries and nearby nerves. Make all efforts to control hemorrhage in a way that will not interfere with subsequent vascular repair by the hand surgeon, including prolonged tourniquet times. While there are conflicting recommendations in the literature regarding safety and length of tourniquet time during hand surgery, 2 hours is the most widely accepted figure.¹⁶ Nerve and muscle injury may result from prolonged ischemia, but reperfusion ("breather") breaks of 5-10 minutes may help if a tourniquet is in place for more than 30 minutes.¹⁷ The Allen test can ensure patency of the ulnar and radial arteries and palmar arches. Perform the Allen test by having the patient clench their fist tightly. Occlude the radial and ulnar arteries and ask the patient to open the blanched hand. Release pressure over one of the arteries and note how long it takes for color to return. If the artery and collaterals are patent, this should occur in 3-5 seconds. Repeat the test in a similar fashion to evaluate the patency of the other artery.

Remove all rings (edema often involves even uninjured fingers) and clean gross blood and debris off the injured hand. Systematically examine the hand, beginning with an overall assessment of the position of the hand and fingers. Note pallor, gross deformity, or phalanges lying in abnormal positions compared to the others. Palpate all bones of the hand and wrist and ensure full range of motion of all joints, noting any tenderness, crepitus, or laxity. Discoloration, edema, and tenderness over a joint may indicate a closed ligament, joint capsule, or tendon injury. Examine the entire hand, since focusing only on apparent injuries may lead to missing the less obvious ones. Deter-

Figure 2. Median nerve test.

In this figure, thumb abduction strength is being checked in a patient whose palm is lying flat while lifting the thumb towards the ceiling. This assesses the abductor pollicis brevis muscle (supplied by a median nerve branch).



mine if any joint capsules are penetrated, which would be an indication for irrigation in the operating room.

Next, assess the sensation and motor strength in the hand to identify nerve injury. The median, radial, and ulnar nerves provide sensation to the hand. Test for sensation of the median nerve at the palmar tip of the index finger, the ulnar nerve at the palmar surface of the little finger, and the radial nerve at the dorsal surface of the web space between the thumb and index finger. Comparative 2-point discrimination is the most accurate assessment of sensation. Intact digital nerves should be able to distinguish points 2-5 mm apart at the fingertips and 7-12 mm at the base of the palm,¹⁸ but this distance may increase with age.¹⁹ When in doubt, compare the injured area with the uninjured hand. While testing sensation, recall that individual digital nerves supply one side of each digit. Lightly stroke ECG calipers, 2 sharp edges of a broken tongue blade, or a bent paper clip in a linear (not transverse) fashion along the palmar surface of the finger to test for this. Loss of sweating distal to the site of injury indicates nerve laceration, as does failure of normal wrinkling of the skin, after soaking the digit of concern in warm water for 30 minutes.²⁰

The median and ulnar nerves provide the entire motor function of the hand (the radial nerve primarily innervates the wrist extensors, and radial nerve injury at the hand should not adversely affect this). Palpate the contracting muscle belly of an injured hand, rather than simply observing it for movement. See **Figure 2** for assessment of the median nerve function. Testing the median nerve motor function by pinching the small finger and thumb together can give false negatives with ulnar nerve injury and should not be used.²¹ Ulnar nerve motor func-

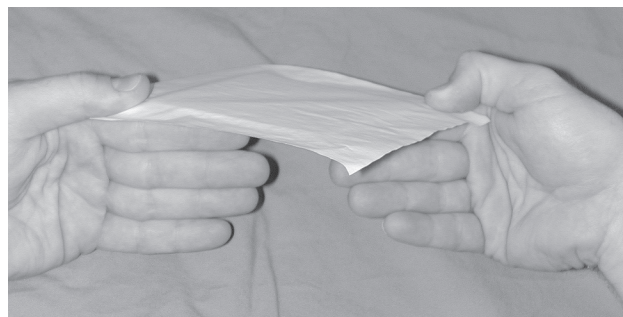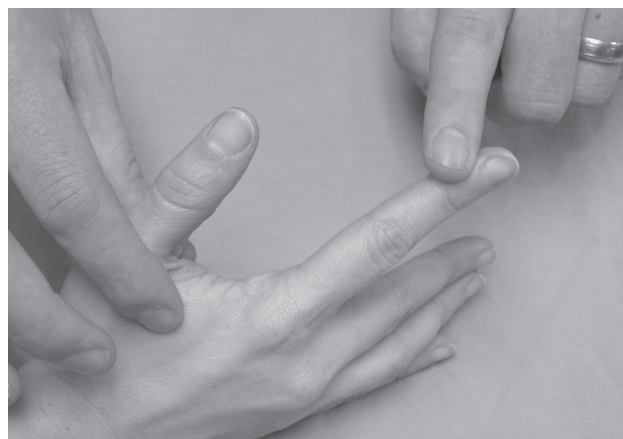tion is tested as shown in **Figure 3**.

Once the neurologic examination has been noted, anesthetize any open wounds prior to exploration (see subsequent section on anesthetic techniques). Failure to provide adequate exposure of deeper wound structures because of patient discomfort often leads to missed injuries. Proper lighting is vital; a portable headlight or overhead direct beam is optimal. Examining a hand in a poorly lighted hall or exam room gives a false sense of reassurance. (*Yes, we've all done it before when the rooms are full in the ED!*) A bloodless field is needed to properly evaluate all but the most superficial hand wounds. Milk the hand or finger with 4X4 sterile gauzes to remove the venous blood after placing a tourniquet. Position a forearm or wrist blood pressure tourniquet as described above, or use a finger tourniquet.²² Excessive pressures in elastic finger tourniquets may be generated, resulting in nerve injury, so use them for shorter time periods (< 1 hour) and do not forget to remove them after finishing the procedure to prevent serious complications!¹⁶

To check for tendon injuries, first assess the hand in a resting position. Since flexor and extensor tendons pull the fingers in opposite directions, complete disruption of

Figure 3. Ulnar nerve tests.

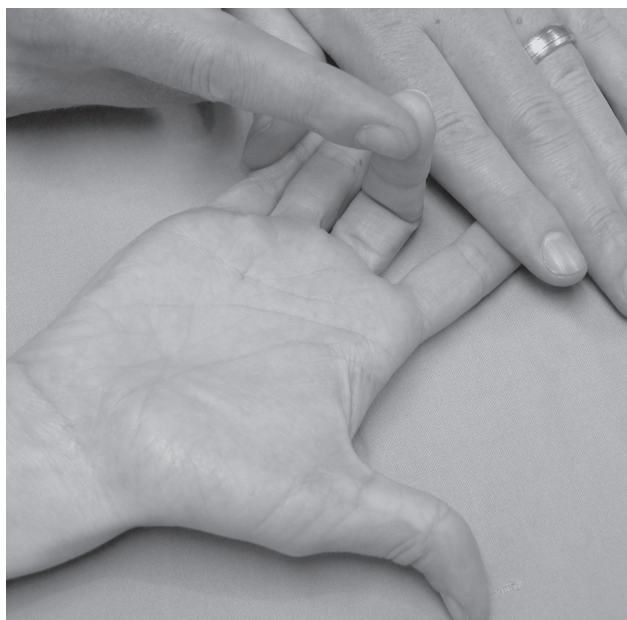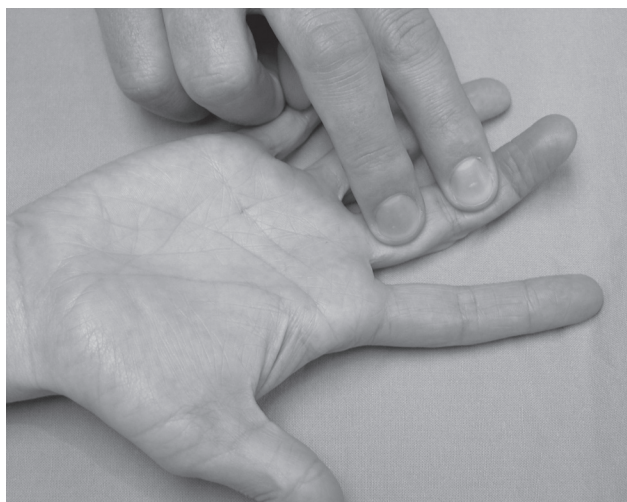
The first image depicts palpation of contraction of the first dorsal interosseous, which verifies ulnar nerve strength. The second image shows Froment's test; the thumb IP flexion on the right indicates compensation for adductor pollicis weakness due to ulnar nerve palsy (positive Froment's sign).



either one may result in the finger resting in a flexed or extended stance in relation to the other fingers. Realize that nearly complete disruption is needed to lose function of an injured tendon. Partial tendon injuries tend to cause more pain than expected in a wound when that tendon is flexed or extended against resistance. Move the hand and fingers through a full range of motion, particularly back to the hand position at the time of injury, to expose tendon injuries that have retracted out of sight from the open wound. Ask the patient to extend the finger against resistance to check for extensor tendon function. Check flexor tendon function as shown in **Figure 4**. If the FDS is severed, the patient is unable to flex the PIP; however, the PIP may flex

Figure 4. Tests of tendon function.

In the first image, the examiner tests FDP tendon function by holding the PIP in extension. In the second image, the examiner tests the FDS by holding the uninvolved fingers flat, while having the patient flex the PIP of the injured finger.



if the FDP is intact and the uninvolved fingers are not held in extension. This is why it is imperative to test both the FDS and FDP separately.

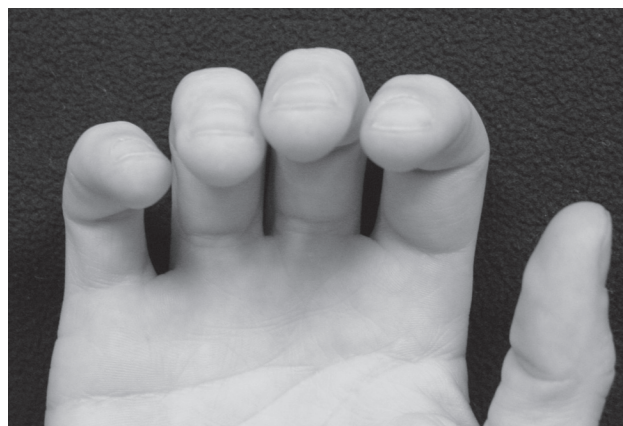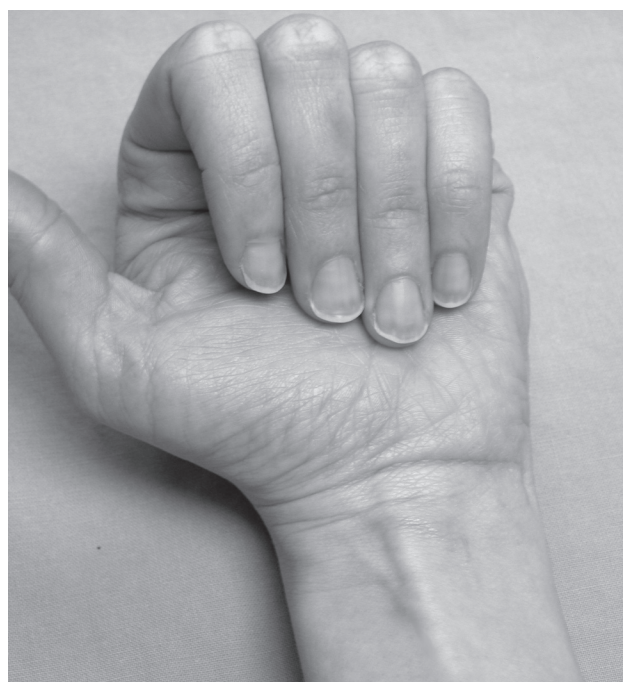
Document any angulation or rotational deformities of the fingers as shown in **Figure 5**.

Radiology

There are no prospective data analyzing specific historical or examination factors that should trigger a provider to or-

Figure 5. Malrotation assessment.

In the first image, all fingers point toward the flexor carpi radialis (visible at the mid volar wrist crease) with normal rotational alignment. However, soft-tissue swelling at the fifth MC may cause apparent malrotation of the little finger ("pseudo-rotation") with this method. A more accurate method to check for malrotation, shown in the second image, may be to assess nail plate alignment with gentle flexion of the fingers. Note that all nail plates lie in the same plane.



der hand radiographs. Despite large discrepancies in clinical suspicion and radiological confirmation of fractures,²⁴ most practitioners order films on patients with significant point tenderness or other external signs of trauma. The American College of Radiology (ACR), Expert Panel on Musculoskeletal Imaging reviewed the current literature on hand imaging and made the following recommendations in 2001:²⁵

1. For suspected metacarpal fracture or dislocation: PA, lateral, and semipronated oblique (off-lateral) view are most appropriate and should be a part of a standard hand series. CT is indicated for patients with equivocal plain films or negative hand series but a strong clinical concern.
2. For suspected phalangeal fractures or dislocations: PA (entire hand or finger only), lateral, and externally rotated oblique are most appropriate and should be obtained. An internally rotated oblique may be appropriate, but does not need to be routinely ordered.
3. For suspected thumb fractures or dislocations: PA or AP of thumb, lateral, PA of entire hand or internally rotated oblique of the thumb are indicated.

CT scanning is recommended for assessment of fracture-dislocations of the carpometacarpal joints and is, in general, more accurate in diagnosing and evaluating bony structures of the hand. Use it when additional radiographic views still do not identify or delineate fractures adequately. The use of ultrasonography in long bone fractures has been advocated, but there are currently no solid prospective data for its use in diagnosing hand or finger fractures. MRI, while indicated for further evaluation of suspected carpal and distal radial injuries, is not recommended in the ACR Appropriateness Criteria for metacarpal and hand fractures. When evaluating suspected gamekeeper injuries, however, MRI is recommended and is more appropriate than stress views, US, or arthrography. Other radiographic modalities for specific injuries will be discussed in subsequent sections here.

ED Management

Anesthesia

As previously stated, providing adequate anesthesia early in the evaluation of hand injuries facilitates full wound exploration. Direct injection of local anesthetics into finger wounds is an option, but this tends to be more painful and less effective than a digital block.²⁶ (For small lacerations, however, direct injection may be useful and less painful.) Wrist anesthesia should also be less painful than direct infiltration, although no studies directly compare the 2 methods prospectively. When anesthetizing fingers, digital block anesthesia is more efficacious with quicker onset of anesthesia than metacarpal block, but both seem equally painful.²⁷ Slow injection using an appropriately sized needle (27-gauge) and a 5 cc syringe should help lessen the pain.

When anesthetizing an injured finger, digital block

using lidocaine buffered with sodium bicarbonate (1 part bicarbonate to 9 parts lidocaine) is less painful upon injection, yet is as effective as plain lidocaine.²⁸ Lidocaine with epinephrine lasts longer than plain lidocaine, decreasing the need for repeat injections, and it provides a less bloody field. Bupivacaine can also be buffered with bicarbonate (1:200), has a longer half-life than lidocaine, and is the authors' preferred anesthetic in conjunction with a digit tourniquet for open injuries.

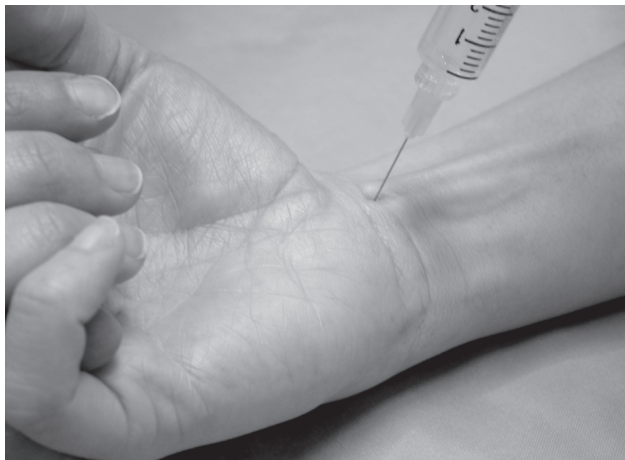A common misconception is that epinephrine should not be used with local anesthetics when performing digital blocks. Several review articles have touted its safety, however, and there have been no case reports of digital gangrene using commercial lidocaine with epinephrine.²⁹⁻³¹ Multiple studies involving thousands of patients support its safety profile, and the decreased digital blood flow has been shown to be temporary, with perfusion being maintained without intervention.³¹⁻³⁵ Most cases of digital gangrene involving epinephrine included other conditions that may have contributed to the complication (large volumes or circumferential injections, hot soaks, tight tourniquets, infection, and unknown or higher epinephrine concentrations based on manual dilution).²⁹ Keep in mind that tourniquet use itself can cause iatrogenic neuropathy. It may also play a role in digital gangrene and necrosis and has not necessarily been proven to be a safer practice than using lower concentrations of epinephrine in digital block anesthetics. Most epinephrine-containing anesthetics used in the ED are 1:100,000 concentration, and lower concentrations such as this have been safely used for digital block. Key points to follow when using digital blocks include:

1. Small amounts of local anesthetics with dilute epinephrine (1:100,00–1:200,000) are probably safe for digital infiltration or blocks.
2. Do not do a circumferential block of the digits.
3. Use small needles to avoid injuring the vessels.
4. Avoid postoperative hot soaks.
5. Buffer the anesthetic.
6. Bandages should not be constrictive or excessively tight.
7. Avoid using epinephrine in patients with vasospastic, thrombotic, or extreme medical conditions.²⁹

To perform a digital block, insert a 27-gauge needle at the dorsal skin of the affected digit, just distal to the MP joint, and raise a small wheal of anesthetic. Direct the needle in a palmar direction and near the edge of the bone of the proximal phalanx, until the needle tip is near the palm. Aspirate to check for blood, withdraw the needle several millimeters, then slowly inject 0.5–1.0 ml of anesthetic. Without completely withdrawing the needle, redirect it across the dorsum of the proximal finger and deposit another 0.5–1.0 ml of anesthetic. Take care not to inject more than 2-3 ml of anesthetic in the adult and use an appropriately smaller volume in children, depending on their size. Large volumes of anesthetic deposited in a circumferential fashion can cause finger ischemia and necrosis.

Figure 6. Median wrist block.

Insert the needle between the flexor carpi radialis and palmaris longus tendons, depositing 5 mL of anesthetic where the nerve passes just beneath the retinaculum.



Wrist blocks are less commonly used by emergency physicians, but they are helpful when a wound is more proximal to the fingers. Block the median nerve at the proximal wrist crease as it passes between the flexor carpi radialis (FCR) and, if present, the palmaris longus. (See **Figure 6.**) Deposit 5 ml of anesthetic underneath the retinaculum, after passing a 25- or 27-gauge needle just ulnar to the FCR. It may take 20-30 minutes for this to take effect. Ulnar nerve blocks can be approached in one of 2 directions. The ulnar nerve lies within a thick neurovascular bundle at the radial aspect of the flexor carpi ulnaris (FCU) tendon (the thick tendon easily palpable at the ulnar aspect of the wrist when flexed against resistance). The ulnar artery lies next to the nerve, so take care not to inject the artery instead. Insert the needle at the radial border of the FCU at the proximal volar wrist crease and advance 1 to 1.5 cm, until you elicit paresthesias, then deposit 5 ml of anesthetic. For the lateral approach see **Figure 7.** A radial nerve block is accomplished by injecting 5–10 ml of anesthetic at a level just distal to the radial styloid.

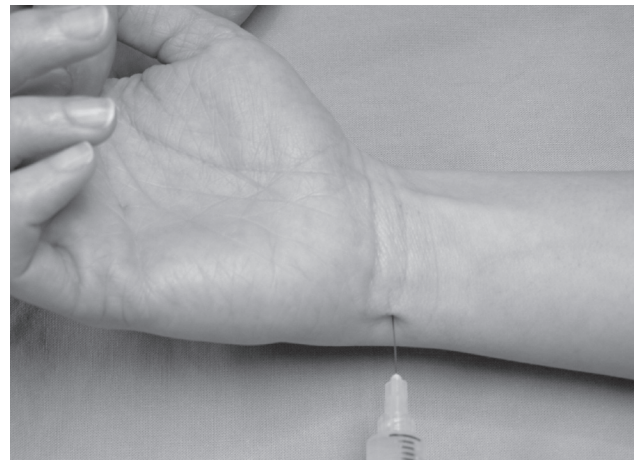
A hematoma block is most commonly utilized for reducing metacarpal fractures in the ED and is rather simple to perform. After properly sterilizing the site, insert a 25- or 27-gauge needle into the hematoma at the fracture site. Aspirate blood and then inject 5–10 ml of anesthetic into the site. Anesthesia is generally achieved in 15–20 minutes, but may not be complete. This procedure is commonly used in the ED, yet few studies have directly compared its efficacy and safety to other methods of analgesia for fracture reduction.³⁶

Splinting

Hand splints are generally applied for fractures, reduced dislocations, ligamentous or tendon injuries, lacerations, burns, or painful contusions. Many patients hold their hands in the wounded position, with wrist and IPs flexed

Figure 7. Ulnar wrist block.

This photo depicts the lateral approach as the needle is passed dorsal to the flexor carpi ulnaris tendon for 1.0-1.5 cm. Once paresthesias are elicited, 5 mL of anesthetic is deposited.



and MPs extended, and failure to immobilize can lead to a nonfunctional and stiff hand. Splints should be placed to immobilize only the necessary joints and allow free motion in all others.

Two similar positions of hand splinting are most commonly recommended by hand surgeons. The safe position is similar to grasping a round glass, with the wrist extended to 30 degrees, the MPs flexed to 60 degrees and the IPs minimally flexed. (See the first image in **Figure 8.**) The intrinsic plus position differs by having slightly more MP flexion (90 degrees) and fully extended IPs. (Second image in **Figure 8.**) Burkhalter described a method of splinting that uses a volar slab of plaster or fiberglass up to the proximal palmar crease to hold the wrist in extension. The MPs must be able to fully flex to allow for the extensor bands to apply a reducing force for fracture reduction, so do not extend the volar slab past the proximal crease.⁸ A dorsally applied slab runs from the forearm to the proximal phalanges, holding the MPs in 90 degrees flexion, but allowing free IP movement. (See **Figure 9** on page 10.)³⁷ This is a good general splint for contusions, metacarpal and proximal/middle phalangeal fractures, and extensor tendon injuries proximal to the PIP. An ulnar gutter (for ring and little finger and metacarpal) and radial gutter (for index and middle finger/MC) splint requires only one slab and should be applied with similar joint immobilization.

Emergency physicians use various finger splints for sprains, fractures, infections, or contusions. Stable nondisplaced fractures, stable dislocation reductions, and IP sprains are generally appropriate for buddy splinting. This type of simple dynamic splinting utilizes the adjacent finger to stabilize the fracture or ligamentous injury, preventing complications while allowing early mobilization during healing. Several simple extension splints are available to treat mallet injuries, and dorsal foam splints

with aluminum backing can be used to immobilize stable injuries of the PIP, DIP, and middle/distal phalanges. Use thumb spica splints to immobilize thumb fractures and ligamentous injuries of the thumb.

Open Wounds

Several irrigation solutions exist for cleansing hand wounds. Regardless of the solution, copious irrigation of an anesthetized open wound, followed by gentle scrubbing and debridement of devitalized tissue, are essential. Some solutions' bactericidal activity is offset by cellular toxicity, which can result in imperfect wound healing or late infections. These include detergent-containing povidone-iodine ("scrub"), hydrogen peroxide, and chlorhexidine.³⁸ On the other hand, normal saline, using high pressure and high volume systems, is effective and nontoxic to tissues. Most authors recommend wound irrigation pressures of approximately 0.5 kilogram-force per square centimeter (kgf/cm²) or 5-10 psi generated by a syringe with an 18-ga angiocath and a minimum of 100 to 300 mL of continuous irrigation.

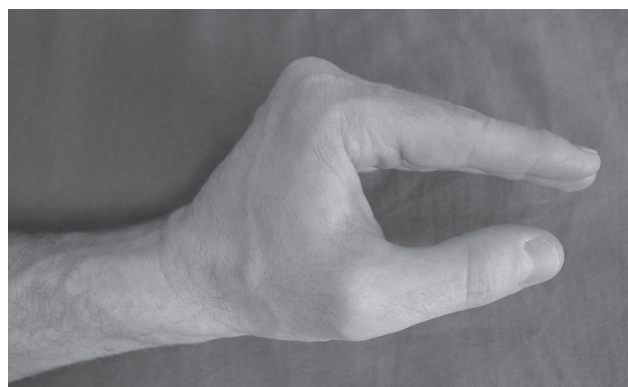
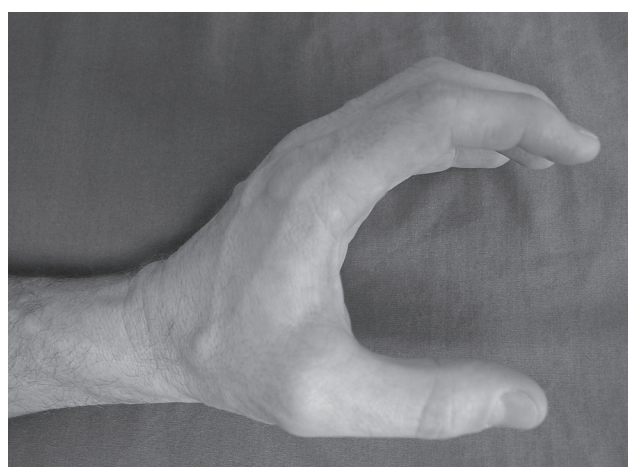
Irrigation with *tap water* is a relatively effortless and time-saving method of cleansing hand wounds. Theoretically,

it may save time, money, and decrease splash risks. In a recent randomized, prospective study of over 500 children with simple lacerations, no significantly different rates of infection (approximately 3%) were found when comparing wounds irrigated with normal saline versus tap water.³⁹ Physicians evaluating the patients on follow-up were blinded to the irrigation methods. Interestingly, twice as many hand wounds, which are generally believed to be more infection prone, were randomized to the tap water group. Tap water pressures generated in this study were about 3-4 kgf/cm², which are fairly representative of most sinks' tap water pressures and higher than some normal saline irrigation systems. The limited evidence suggests that this technique may be efficacious and especially practical for cleansing hand wounds.

Cleansing hand wounds with *povidone-iodine solution* (Betadine®) is a controversial subject with conflicting evidence. Higher concentrations have proven to be tissue-toxic, but there are no studies specifically assessing hand wounds to confirm these findings. In one study, there was no significant difference in infection rates between wounds irrigated with 1% povidone-iodine and normal saline.⁴⁰ In another prospective trial, sutured hand lacerations treated with povidone-iodine dry powder aerosol spray vs control had similarly low infection rates, side effects, and imperfect healing rates.⁴¹ Soaking of wounds in any solution appears ineffective in decreasing bacterial counts. The use of povidone-iodine solutions greater than 1% should be avoided.⁴² There are no studies of hand wounds showing that any solution or method is significantly more efficacious than high-pressure, normal saline irrigation.

Figure 8. Recommended splinting positions.

The first image shows the "safe" position of the hand; the second image depicts the intrinsic plus position.



Foreign Bodies

Hand wounds are notorious for harboring foreign bodies, and managing these often poses a clinical challenge to even the most experienced emergency physicians. Much has been written on retained foreign bodies in traumatic wounds. The literature reviewed for this section focused specifically on hand wounds, since the sensation and anatomy of the hand may make the assessment of wounds here different from other body areas. In a review from a large medical malpractice insurance company, over a third of closed claims involved retained foreign bodies in finger/hand/arm wounds.⁴⁶

Good wound exploration should identify most foreign bodies. This is more sensitive if the wound is probed, palpated, and the wound base is visualized, but studies suggest these measures alone are insufficient to completely exclude retained glass or other foreign bodies.^{14,47,48} Retained glass is the most commonly reported retained hand foreign body, and mechanisms usually involve glass shattering in a hand or an upper extremity breaking through a glass window. Plain radiographs are very sensitive in picking up all types of glass foreign bodies > 2 mm in size.⁴⁹ Radiographs also identify rocks, gravel, metal, and other radio-opaque foreign bodies, but only rarely pick up plastic, wood, or other vegetable matter. Retained foreign bodies do increase infection rates, though

small foreign bodies deeply embedded may be best left in place.^{46,50,51}

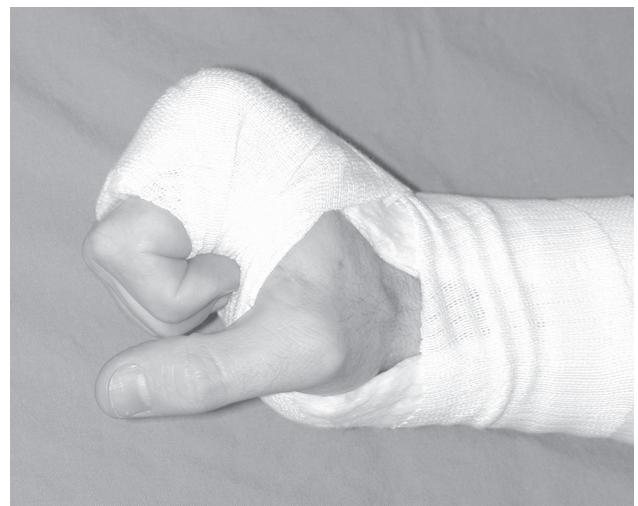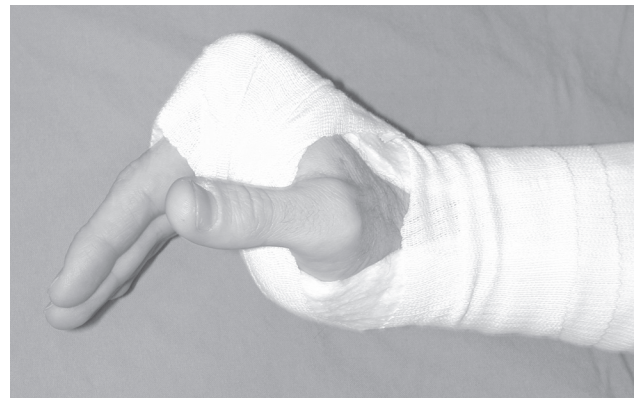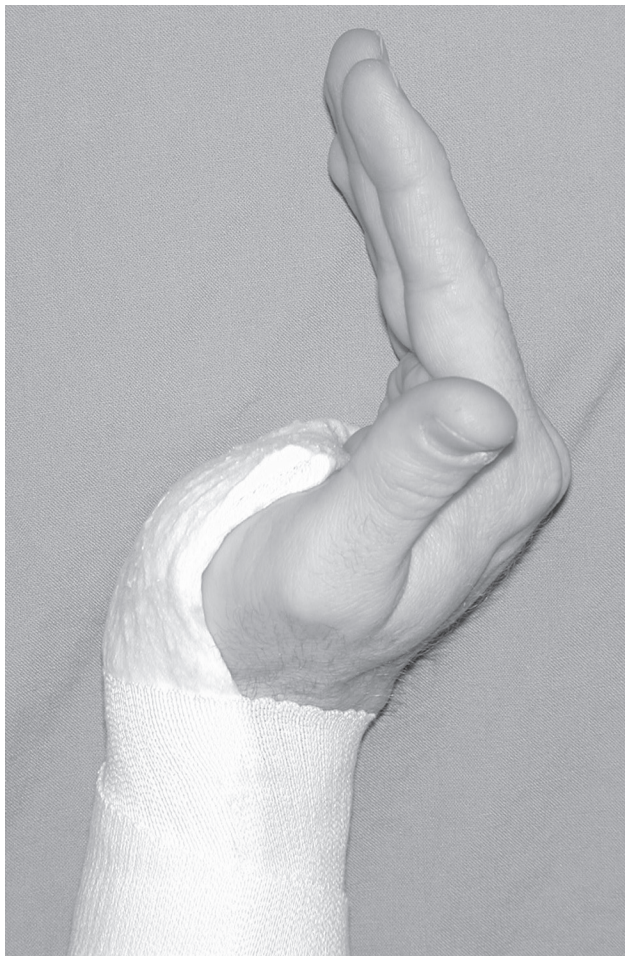If the wound appears clear and the initial x-rays are normal, further studies may be indicated when a radiolucent foreign body is suspected. Multiple studies report the usefulness of ultrasound in detecting soft tissue foreign bodies,⁵²⁻⁵⁴ although one randomized, controlled prospective study using a chicken-thigh model to simulate hand anatomy differed in opinion.⁵⁵ Perhaps the best existing RCT evaluating sonography in hand foreign bodies was performed on human cadaver hands with sensitivities of 95-100% for small (1-4 mm) and larger wooden foreign bodies of the palm and fingers.⁵⁶ The accuracy of ultrasound performed by emergency physicians to detect wound foreign bodies has yet to be prospectively studied. CT evaluation of wound foreign bodies is also very sensitive and, although generally more expensive than ultrasonography, is more readily available and less expensive than MR imaging.⁵⁷

Bite Wounds

Bite wounds are responsible for nearly 1% of all ED visits in the United States, with dog bites accounting for 80-90% of cases.⁵⁸ In one prospective study, 50% of infected dog bites and 63% of infected cat bites occurred on the hand.⁶⁰ In a systematic Cochrane review in 2003, the authors concluded that there is no evidence that prophylactic antibiotics are effective for cat or dog bites, with *one notable exception*: bite wounds to the hand.⁶¹ Prophylactic antibiotics significantly reduced the incidence of infection from 28% in the control group to 2% in the antibiotic group, when the bite wound affected the hand. The third most common bite wound in the United States is the human bite, and these frequently cause significant infections.^{58,62} In a prospective, randomized study comparing placebo, oral antibiotics, and intravenous antibiotics in the management of uncomplicated human bites to the hand, nearly half of the admitted patients not receiving antibiotics developed an infection.⁶⁴ None of those receiving oral or intravenous antibiotics developed an infection. For a detailed discus-

Figure 9. Two-slab splint as described by Burkhalter.

The volar slab is placed first to hold the wrist in 30° extension (first image); then the dorsal slab is placed to the PIP joints with the MPs held at 90° extension (second image). Note free movement of the IP joints (third image).



sion of bites, see *Emergency Medicine PRACTICE*, Volume 5, Number 8, Dog, Cat, And Human Bites: Providing Safe And Cost-Effective Treatment In The ED, August 2003.

High-Pressure Injection Injuries

Emergency medicine physicians should act aggressively when treating high-pressure injection injuries, since they carry a high incidence of significant complications, including amputation.^{68,69} Spray guns, grease guns, and diesel injectors account for the majority of cases.⁷⁰ Important historical details include the type and amount of material injected, the time since the injury occurred, the anatomic location of the injection, and (if possible) the velocity of the material injected. The rate of amputation after injection with paint, paint thinner, and solvents is greater than 60%, compared to an amputation rate of less than 10% from hydraulic fluid injections. Delays in treatment may lead to increased morbidity and, in one report, all patients ultimately requiring amputations presented for treatment between 6-48 hours after injury.⁷¹ Injection of the volar aspect of the fingers and underlying flexor sheaths resulted in an amputation rate of the digit in 50% of cases, while none of the patients with hand entry wounds needed amputation.⁷¹

Order radiographs, since grease creates lucencies on plain films, lead-based paints create areas of opacification, and non-lead-based paint manifests as subcutaneous emphysema. Provide pain control with intravenous analgesics, since digital or local anesthetic blocks have been associated with worse outcomes.⁶⁹ Currently, no prospective, controlled trials studying high-pressure injection injuries exist. However, several authors advocate the use of both tetanus prophylaxis and prophylactic antibiotics, even though injected matter may actually have antimicrobial activity.⁶⁹ Systemic steroids have been suggested by several authors to decrease the inflammatory response, but no prospective data support their use.^{71,72} The key in managing the patient with a high-pressure injection injury to the hand is immediate consultation to a hand surgeon

for decompression, exploration, and debridement.

Nerve Injuries

Digital nerve injuries proximal to the DIP crease on the radial aspect of the index and middle fingers, the ulnar aspect of the little finger, and both sides of the thumb should be repaired. A hand surgeon should also repair lacerations of all motor branches of the ulnar and median nerves. Timing of repair is controversial, since some data suggest better results with primary repair (at time of injury or within 6-12 hours) of simple, clean nerve injury,^{73,74} while other data show acceptable results with delayed repair.^{75,76} Nerve injury with contaminated wounds or crush injuries with extensive soft tissue damage should be repaired in a delayed manner, after wound healing. Results of nerve repair between 3 weeks and 3 months post-injury are generally good. Consult a hand specialist to obtain his or her preference when deciding the correct timing of nerve injury repair.

Hand Burns

An estimated 2-3 million burned patients are evaluated in EDs per year, and nearly 90% of these burns affect the hands.⁷⁷⁻⁷⁹ The goal of management is preservation of both skin and hand function. (For an in-depth discussion of burns, see *Emergency Medicine PRACTICE*, Volume 2, Number 9, Thermal Burns: Rapid Assessment And Treatment, September 2000.) Hand burns are caused by a number of etiologies, some of which have unique management issues, eg, hot tar⁷⁷ and hydrofluoric acid.

Thermal hand burns are treated with analgesia, debridement, topical therapy, dressings, and splinting.⁸⁰ After administering adequate analgesia, clean the wound of contamination and debride peeled skin. Small blisters (< 1 cm in diameter) can be left intact to act as a biological dressing that protects against infection; larger blisters may benefit from debridement.⁸¹ Apply silver sulfadiazine or bacitracin for topical antibiotic coverage. Note that prophylactic systemic antibiotics have not been proven

Cost-Effective Strategies For Managing Hand Injuries

1. Use a bent paper clip to check for 2-point discrimination.
Easy to find in the ED and disposable!

2. Explore all hand wounds fully.
Will save *everyone involved* significant costs, if you identify the foreign body or underlying injury on initial examination.

3. Irrigate wounds with tap water.
Tap water is cheaper than normal saline and you can put the patient to work.

4. Let smaller hand wounds (< 2 cm) heal by secondary intention.

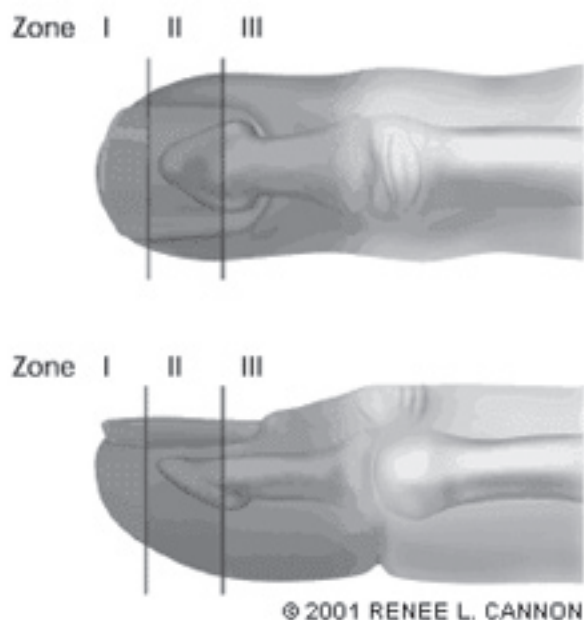
Costs of suture kit, suture material, procedure, and suture removal visit all add up and may be unnecessary for small wounds.

5. Withhold antibiotics for simple, clean lacerations to the hand.
Even sutured wounds of this type may do well if properly irrigated. High-risk factors, such as bite wounds, crush injuries, or contamination, generally require antibiotics.

6. Remove all rings from injured extremities.
This simple strategy may prevent complications for the inevitable delayed swelling due to injury. ▲

to prevent infections.⁷⁷ Apply bulky gauze dressings with gauze placed between each of the fingers and held in place by rolled gauze bandages. When treating only superficial, partial thickness wounds, place the fingers in a position of comfort. Splint hands with deep-partial thickness and full-thickness wounds with IP joints in full extension, MP joints flexed at 80-90 degrees, and the wrist extended at 20-30 degrees.⁸¹ This position stretches collateral ligaments to maximum length and may help prevent the boutonniere deformity.

Figure 10a. Fingertip amputation zones.



Fingertip Amputations

The fingertip amputation is a common injury seen in the ED, and the most important goal in treatment should be preserving a digit with a sensitive, functional tip. Preservation of length is important, especially when treating injury to an index finger or thumb.⁸² Therapy can be directed by classifying fingertip injuries into zones. (See **Figures 10a and 10b.**) Zone I injuries are treated conservatively with debridement, meticulous wound care, and antibiotic ointment dressing. Zone II and III injuries generally require a skilled hand surgeon.

Nail Bed Injuries

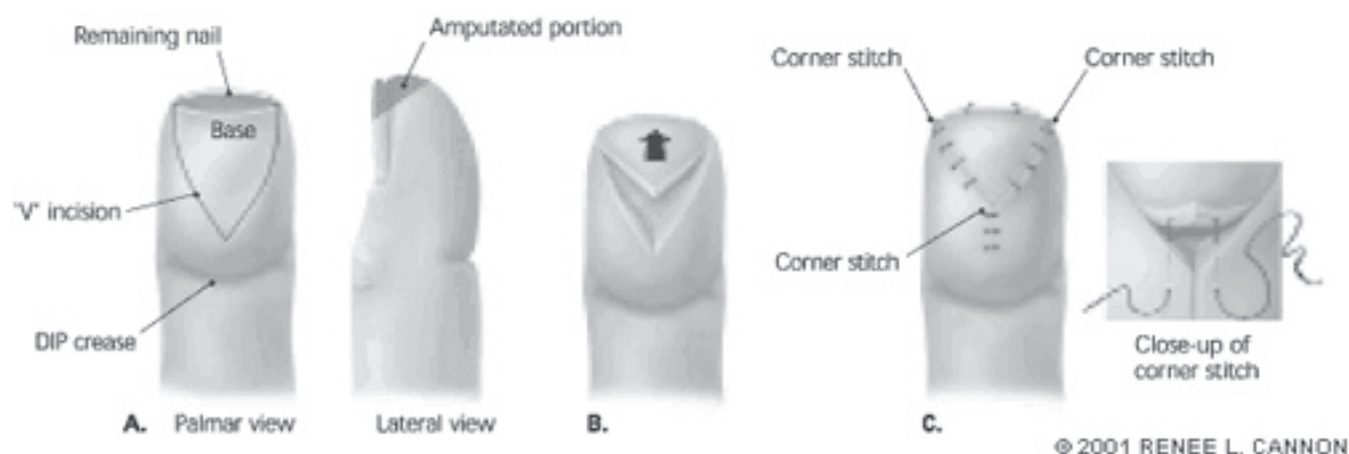
Historically, the presence of a subungual hematoma greater than 25% of the nail bed was an indication for removal of the nail plate to evaluate for nail bed laceration, since unrepaired lacerations may cause cosmetic deformities.⁸⁴ Other authors suggest that exploration is warranted in the presence of both a distal phalanx fracture and a subungual hematoma that involves greater than 50% of the nail bed.⁸⁵ This practice has been questioned in recent years, and limited evidence suggests it may be unnecessary.^{86,87} Based on the best available evidence, either trephinate or leave alone nail plates that are still adherent to the nail bed with intact nail folds.⁸⁸ Remove the nail plate and repair nail bed lacerations when the nail fold is disrupted or the nail is dislodged from the underlying bed.

Dislocations

Dislocations and ligamentous injuries are common and range from mild sprains to complete rupture of the ligaments supporting the joints. Test stability and range of motion of the affected joint, although this may be difficult,

Continued on page 16

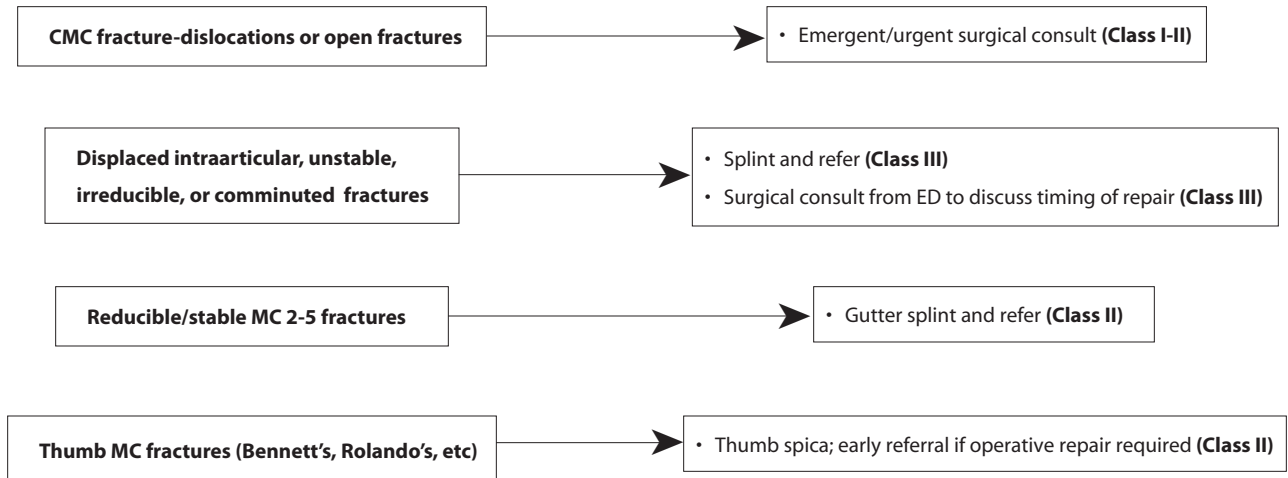
Figure 10b. Fingertip amputation zones.



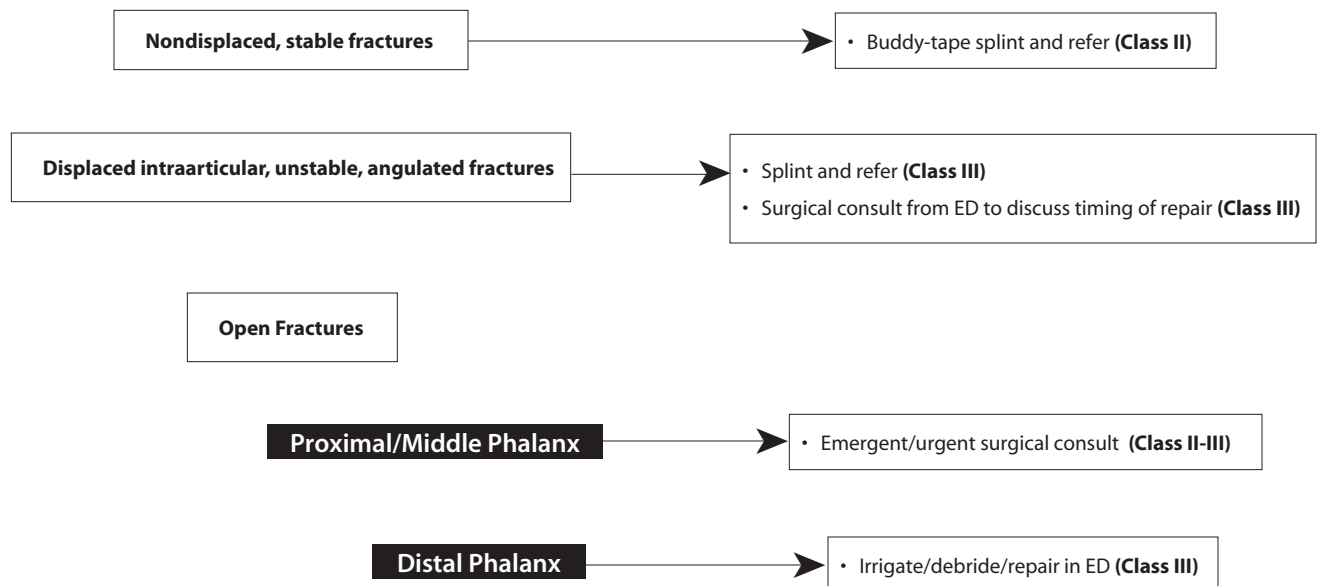
Used with permission from: Jackson EA. The V-Y plasty in the treatment of fingertip amputations. *Am Fam Physician* 2001 Aug 1;64(3):455-458. Figures 1 and 3.

Clinical Pathway: Management Of Hand Injuries

Metacarpal Fractures



Finger Fractures




The **evidence for recommendations** is graded using the following scale. For complete definitions, see back page. **Class I:** Definitely recommended. Definitive, excellent evidence provides support. **Class II:** Acceptable and useful. Good evidence provides support. **Class III:** May be acceptable, possibly useful. Fair-to-good evidence provides support. **Indeterminate:** Continuing area of research.

This clinical pathway is intended to supplement, rather than substitute for, professional judgment and may be changed depending upon a patient's individual needs. Failure to comply with this pathway does not represent a breach of the standard of care.

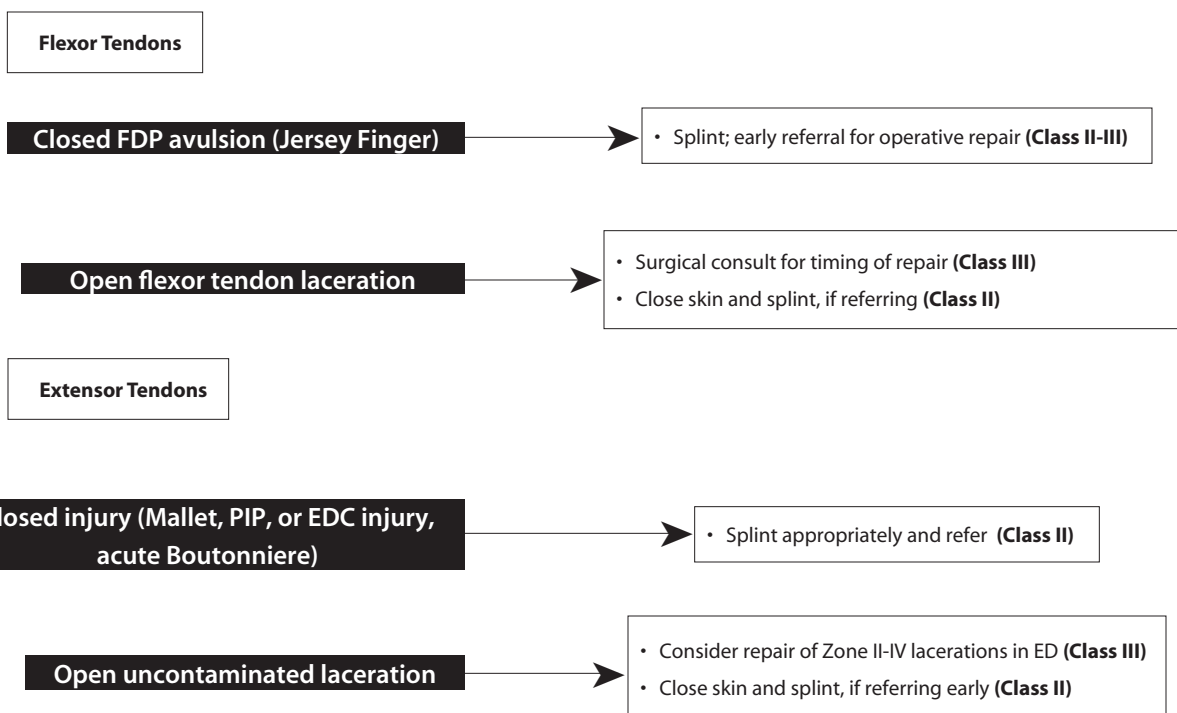
Copyright ©2005 EB Practice, LLC. 1-800-249-5770. No part of this publication may be reproduced in any format without written consent of EB Practice, LLC.

Clinical Pathway: Management Of Hand Injuries (continued)

Dislocations/Ligament Injuries



Tendon Injuries



The **evidence for recommendations** is graded using the following scale. For complete definitions, see back page. **Class I:** Definitely recommended. Definitive, excellent evidence provides support. **Class II:** Acceptable and useful. Good evidence provides support. **Class III:** May be acceptable, possibly useful. Fair-to-good evidence provides support. **Indeterminate:** Continuing area of research.

This clinical pathway is intended to supplement, rather than substitute for, professional judgment and may be changed depending upon a patient's individual needs. Failure to comply with this pathway does not represent a breach of the standard of care.

Copyright ©2005 EB Practice, LLC. 1-800-249-5770. No part of this publication may be reproduced in any format without written consent of EB Practice, LLC.

Clinical Pathway: Management Of Hand Injuries (continued)

High-pressure Injection Injury

- X-ray (**Class III**)
- Avoid digital blocks (**Class III**)
- Tetanus prophylaxis (**Class I-II**)
- IV antibiotics (**Class III**)
- Emergent/urgent surgical consult (**Class II**)

Bite Wounds

Dog or Cat

- Careful history of attack detailing rabies risk
- Rabies/tetanus prophylaxis, if warranted
- Irrigation, exploration, and debridement (**Class II**)

Injury to tendon, vessel, or joint?

NO

YES

- Prophylactic antibiotics (**Class II**)
- Outpatient follow-up

- Emergent/urgent consultation (**Class II**)

Human

High Risk? (Clenched fist; injury to tendon, vessels, or joint; infection)

- Emergent/urgent consultation (**Class II**)

Less Risk? (Simple occlusional; no signs of infection)

- Prophylactic antibiotics (**Class II**)
- Close outpatient follow-up

Hand Burns

High Risk? (Deep partial thickness; full thickness; fourth degree; significant chemical burn; significant electrical injury)

- Emergent/urgent consultation (**Class III**)
- Referral to burn center (**Class III**)

Superficial partial thickness

- Debride blisters > 1cm (**Class III**)
- Leave blisters < 1cm intact (**Class III**)
- Topical coverage with bacitracin or silver sulfadine (**Class III**)
- Bulky gauze dressing in position of comfort (**Class III**)

- Pain controlled with oral medication?
- Home environment supportive?
- Family able to perform dressing changes?
- No suspicion of abuse?
- Adequate follow-up assured?

NO

YES

- Emergent/urgent consultation (**Class III**)

- Discharge with next-day follow-up (**Indeterminate**)

The **evidence for recommendations** is graded using the following scale. For complete definitions, see back page. **Class I:** Definitely recommended. Definitive, excellent evidence provides support. **Class II:** Acceptable and useful. Good evidence provides support. **Class III:** May be acceptable, possibly useful. Fair-to-good evidence provides support. **Indeterminate:** Continuing area of research.

This clinical pathway is intended to supplement, rather than substitute for, professional judgment and may be changed depending upon a patient's individual needs. Failure to comply with this pathway does not represent a breach of the standard of care.

Copyright ©2005 EB Practice, LLC. 1-800-249-5770. No part of this publication may be reproduced in any format without written consent of EB Practice, LLC.

due to pain and swelling. Apply a digital or wrist block to assist with this, if necessary. Document areas of tenderness and swelling, and gently stress the joint with dorsal-volar, radial-ulnar force, to check for laxity and subluxation.

The volar plate and collateral ligaments form a box-like structure around the MP and IP joints. Dislocation and instability imply a complete tear of the volar plate and/or the collateral ligaments, while swelling and tenderness point to a partial tear or sprain. Order radiographs to document associated fractures and postreduction success. Mild sprains can generally be buddy-taped with early active protected motion, but more significant injuries require at least several weeks of immobilization, if not operative intervention. (See **Table 2** for common injuries and management recommendations.) Refer significant injuries to a hand surgeon for formal splinting and evaluation for possible surgical repair. Stiffness and loss of flexion are common for ligamentous injuries. An experienced consultant should direct management early, instituting active

range-of-motion exercise and physical therapy as soon as possible.

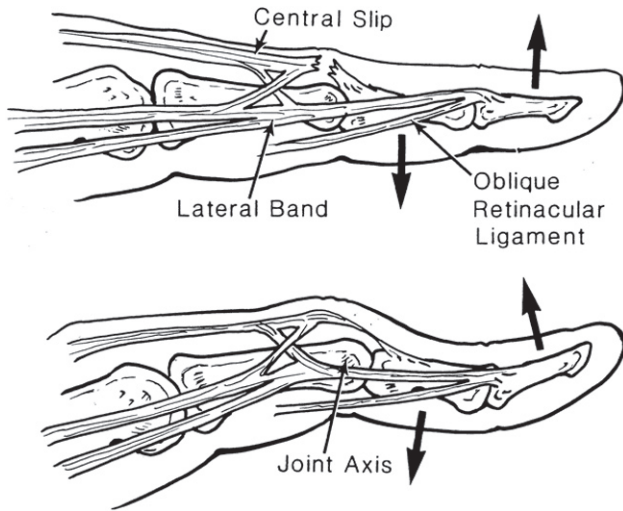
DIP Joints

DIP dislocations are most often dorsal and associated with an open injury. After placing a digital block, apply longitudinal traction and hyperextension, then a dorsal pressure to the distal phalanx to reduce a dorsal dislocation. Irreducible dislocations resulting from entrapment of an avulsion fracture or FDP, or from a buttonhole tear in the volar plate, require operative reduction.⁸⁹ Copiously irrigate open injuries after reduction. Close the skin, give antibiotics, and splint with slight DIP flexion. Splint closed and stable DIP reductions in a neutral position and encourage early, active range of motion. If unstable, the injury will first need to be splinted in 20 degrees flexion for 2-3 weeks before starting active range of motion.⁸ Refer open or unstable DIP dislocations to a hand surgeon for reevaluation.

Table 2. Hand Dislocations And Ligamentous Injuries.

Injury/Location	Management
Distal IP Joint	
•Reducible-stable dislocation, collateral ligament injury	•Splint DIP neutral (mallet type splint); immediate active ROM
•Reducible-unstable dislocation	•Aluminum foam splint, DIP 20 degrees flexion for 2-3 wks, then active ROM
•Irreducible dislocation, profundus avulsion	•Consultation from ED for operative repair
Proximal IP Joint	
•Reducible-stable dislocations (usually dorsal or lateral)	•Buddy-tape for 2-4 wks; refer to hand surgeon in 5-7 days
•Irreducible, open, or reducible-unstable dislocations	•Consult from ED for open reduction and repair
•Reducible volar dislocations	•Consult from ED for open repair or extension splinting for 4-6 wks
MP Joint	
•Reducible dorsal dislocations and collateral ligament rupture	•Burkhalter or Gutter splint with MP in 50 degrees flexion, refer in 5-7 days
•Complex/irreducible dorsal dislocations, volar dislocations, index finger radial collateral	•Consult from ED for operative repair
Thumb IP Joint	
•Reducible-stable dorsal dislocation	•Aluminum foam splint with 20 degrees IP flexion for 3 wks
Thumb MP Joint	
•Reducible-stable dorsal dislocations	•Thumb spica splint with 20 degrees MP flexion for 4 wks; refer
•Partial (stable) UCL tear or radial collateral injury	•Thumb spica splint for 4 wks; refer 5-7 days
•Volar or irreducible dislocation or complete UCL tear	•Consult from ED for operative repair
Carpometacarpal Joint	
•Finger CMC dislocation	•Consult from ED for operative repair
•Thumb CMC dislocation, reduced	•Consult from ED for operative repair; thumb spica, if referred

Figure 11. Boutonniere deformity.



Used with permission from: Rockwell WB, Butler PN, Byrne BA. Extensor tendon: anatomy, injury, and reconstruction. *Plast Reconstr Surg* 2000 Dec;106(7):1592-1603. Figure 8.

PIP Joints

The PIP joint is the most frequently dislocated hand joint. Complications are significant and common, due to the joint's complex biomechanics. Joint instability, poor function, pain, and flexion deformities were found in 30% of patients in one review.⁹⁰ In addition to standard joint testing, have the patient try to extend the PIP against resistance while in 90 degrees flexion. If the patient is unable to extend the PIP while the DIP is extended, a complete rupture of the central slip, which results in an acute boutonniere deformity, should be highly suspected. (See **Figure 11** on next page.)⁹¹⁻⁹⁴

Thumb MP Joint Dislocation

This joint is frequently injured, because of the thumb's relatively vulnerable position. These dislocations may result in dorsal and volar plate entrapment, causing a complex and irreducible dislocation here, as well. To reduce simple dorsal dislocations, first apply median and radial nerve blocks. Flex and adduct the MP joint with thumb IP and wrist flexion, then apply dorsal pressure to the proximal phalanx base. Test the collateral ligaments for stability; ulnar or radial collateral ligament damage requires further assessment and more detailed management (see below). If the thumb MP is stable, place a thumb spica splint with 20 degrees MP flexion for 4 weeks. Complex or irreducible dislocations, or joints with significant instability, need operative repair.

Ulnar Collateral Ligament Injury (Skier's or Gamekeeper's Thumb)

"Gamekeeper's Thumb" is an acute or chronic injury

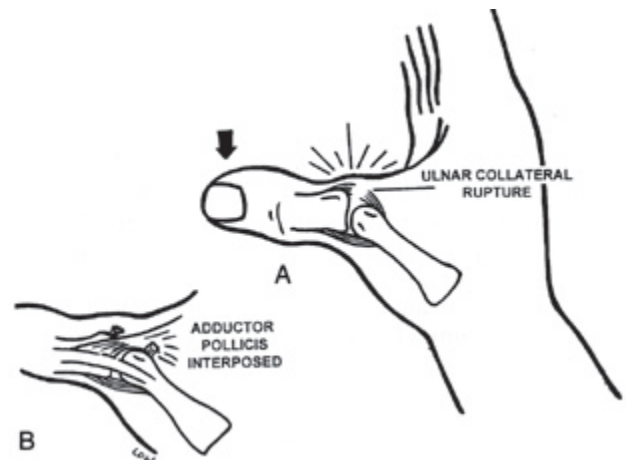
to the thumb ulnar collateral ligament (UCL). The term originates from a report of Scottish gamekeepers, who had injuries to their ulnar collateral ligaments while breaking the necks of wounded hares — although the article described a chronic laxity rather than acute injury. Today the so-called Gamekeeper's Thumb results most often from ski-pole and football injuries, as the ligament is damaged by forced extension and abduction of the thumb. Typically, the completely torn UCL becomes trapped proximal to the adductor pollicis aponeurosis, as in **Figure 12**. Referred to as a Stener lesion, this complication leads to improper healing and an increase in chronic disability, if not surgically corrected.⁹⁵ On physical examination, there is edema and tenderness at the dorso-ulnar aspect of the thumb MP joint, along with weakness of pinch. Presence of a complete tear and subsequent laxity of the UCL may be present, but this is difficult to assess.^{96,97} Obtain plain radiographs on these types of injuries to identify an underlying avulsion or condylar fracture. Place patients with any suspected UCL injury in a thumb spica splint and refer them for further evaluation.

Radial Collateral Ligament Injury

Injuries to the radial collateral ligament of the thumb MP joint are less common, but can also result in chronic pain and laxity.¹⁰¹ There is no risk for a Stener-like lesion, and therefore most heal well with nonoperative treatment. Place the patient in a thumb spica splint and refer to a hand surgeon.

Figure 12. Ulnar collateral ligament rupture and Stener lesion.

Image A shows an ulnar collateral ligament rupture, while image B shows a Stener lesion. The entrapment of the adductor pollicis aponeurosis between the torn ends of the ulnar collateral ligament may delay or prevent proper healing of this injury.



Used with permission from: Harrison BP, Hilliard MW. Emergency department evaluation and treatment of hand injuries. *Emerg Med Clin North Am* 1999 Nov;17(4):793-822, v. Figure 11 (A, B).

Tendon Injuries

Open and closed tendon injuries to the hand require special attention to prevent long-term sequelae. Examine the injured hand methodically for these injuries, which are sometimes subtle and difficult to identify. Determine the position of the hand during injury, the time of injury, the mechanism of injury, and any changes in function and strength in the hand. Check tendon motion against resistance, since partial tendon lacerations may still have a normal range of motion. Limited or painful movement (or more than would be expected with the laceration or contusion) suggests partial involvement of a tendon. Adequate exposure and anesthesia of the wound is vital to prevent missed tendon involvement.

Most flexor and extensor tendon injuries require repair by a hand surgeon, but certain extensor injuries are amenable to repair by the emergency physician (see below). Leave wounds open with tendon involvement from bites, crush injury, or other significant contamination and consult a hand surgeon from the ED. Start prophylactic antibiotics, if referring for delayed repair. In relatively "clean" wounds with flexor tendon involvement, there is no evidence that prophylactic antibiotics are necessary.¹⁰³ Irrigate and debride all open wounds, as previously described. In cases of non-contaminated tendon injuries that are being referred to a hand specialist for repair, loosely suture the overlying skin and splint the hand appropriately.

Flexor Tendon Injuries

Most flexor tendon injuries are open. Avulsion of the FDP is the most common closed injury and usually results from forced extension of a flexed DIP joint (ie, the athlete grasping at a running opponent's jersey, or "Jersey Finger"). These patients will present with the affected DIP held in extension and pain at the volar surface of the DIP. They will be unable to flex the DIP with the examiner holding the PIP in extension.

Flexor tendon injuries should be referred early to a hand surgeon, since most recommend repairing complete lacerations primarily no later than 12-24 hours after injury. The results of primary, delayed primary (< 10 days), or early secondary (2-4 weeks) repair show little difference in outcomes, but late secondary repair (> 4 weeks) is not as successful.¹⁰³⁻¹⁰⁶ Some questions remain regarding the necessity for repair of partial flexor tendon injuries, although most hand surgeons only repair flexor tendon injuries which involve more than 50% of the tendon surface.¹⁰⁷ Synovial adhesions, triggering, entrapment, and delayed tendon rupture are complications that may occur *whether or not* the tendon is repaired.^{108,109} Newer data suggest not repairing flexor tendon lacerations involving less than 75% of the cross-sectional area of the tendon, unless triggering is a problem. Consult a hand surgeon for recommendations regarding the timing and appropriateness of flexor tendon injury repair. Splint the injured hand with 30 degrees wrist flexion, 70 degrees MP flexion, and slight IP flexion.

Table 3. The Verdan Extensor Tendon Injury Classification System.

Zone	Anatomic Location
I	DIP Joint
II	Middle Phalanx
III	PIP Joint
IV	Proximal Phalanx
V	MCP Joint
VI	Metacarpals
VII	Carpals
VIII	Proximal Wrist

*Source: Kleinert HE, Verdan C. Report of the Committee on Tendon Injuries (International Federation of Societies for Surgery of the Hand). *J Hand Surg [Am]*. Sep 1983. See Reference 112.

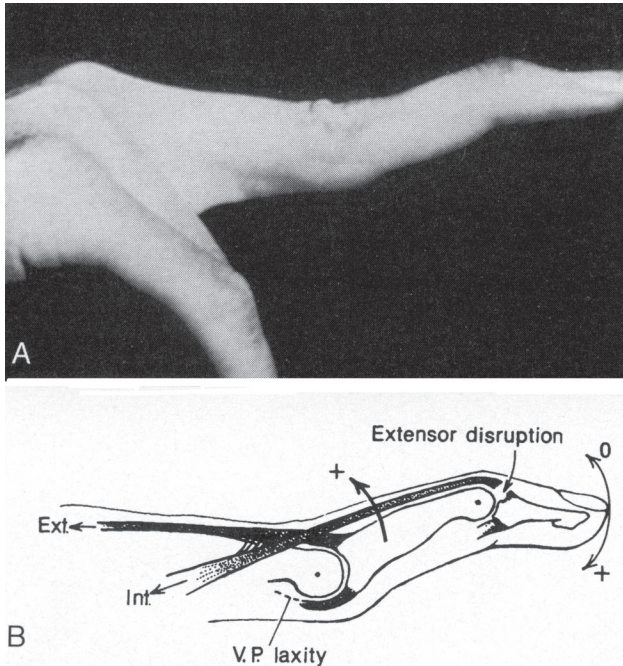
Extensor Tendon Injuries

Dorsal hand wounds often involve extensor tendons, because of their superficial lie and thin overlying skin. The extent of injury may be underestimated in the ED, so optimal outcomes are not always obtained.^{110,111} It is generally best to coordinate the repair with a hand surgeon willing to provide follow-up. Repair partial extensor tendon lacerations with absorbable, synthetic material such as Vicryl®. Suture complete tendon lacerations with polyester, nonabsorbable materials, such as Ethibond® or Mersilene. Sutures of size 4-0 are usually appropriate for tendon repair, with 5-0 being reserved for smaller size tendons. Although no prospective data on the treatment of *partial* extensor tendon lacerations exist, clinicians often extrapolate the data from partial flexor tendon lacerations to partial extensor tendon injuries. Many consultants thus advocate repairing only those extensor lacerations which involve > 50% of the tendon cross-surface area.

The hand and wrist are divided into anatomical zones to help classify tendon injuries. The commonly used system developed by Verdan uses 8 zones to help assess injuries and guide treatment based on the location of injury. (See **Table 3**.)¹¹² Zone I and II injuries involve the conjoint tendon or terminal extensor mechanism of the distal 2 phalanges. These occur from closed or open mechanisms and may result in some degree of mallet deformity of the distal phalanx. The mechanism of injury is usually an axial load on the fingertip, which forceful flexes of the DIP while it is held in extension and results in a "Mallet Injury."¹¹³ Late complications of untreated mallet injuries include a "swan-neck deformity" from proximal and dorsal displacement of the lateral bands, causing hyperextension of the PIP and flexion of the DIP, as in **Figure 13**.

Zone III injuries involve the tendons surrounding the

Figure 13. Swan neck deformity.



Used with permission from: Green DP, Hotchkiss RN, Pederson WC, eds. *Operative Hand Surgery*. Vol 1. New York: Churchill Livingstone; 1999:2016. Figure 62.28.

PIP joint. Closed injuries are from axial loading or a dorsal blow to the PIP, while open lacerations usually involve the central slip. There may be a resting extension lag of the PIP or a swollen, tender joint that is weak and painful with extension. Treat closed injuries with PIP extension splinting for 6 weeks. Repaired, open injuries need splinting for 3-6 weeks with the PIP in a neutral position, MP at 15-30 degrees flexion, and wrist in 30 degrees of extension. The boutonniere deformity usually presents several weeks after a closed injury, but may present acutely in either open lacerations or closed injuries with an associated bony avulsion off the middle phalanx. Refer these to a hand surgeon for repair.

Zone IV injuries over the proximal phalanx are usually due to lacerations and may be primarily closed, with the PIP splinted in extension for 6 weeks. Closed injuries may be splinted with the PIP in extension for 3-4 weeks, and early motion should be considered.¹¹³ If underlying phalanx damage is present, refer early to a hand surgeon. Tendon adhesion to the underlying periosteum is a common complication.

Zone V injuries involve the MP and are usually open: a human bite must be ruled out first and foremost. Open lacerations may involve both the sagittal bands and EDC tendons, which must be repaired by a hand surgeon or experienced emergency physician. Place a Burkhalter splint with the wrist in 45 degrees extension, the MP in 15 degrees of flexion, and the PIP free. Closed injury (direct blow to the MP) may cause tearing of the extensor hood

and ulnar deviation of the EDC, which is treated with extension splinting of the MP for 4-6 weeks. Refer for early dynamic splinting.

Zone VI tendons are very superficial and easier to diagnose and repair. Due to the attached *junctura tendinae*, the severed ends tend not to retract. After repair, splint with the wrist in 30-45 degrees of extension, the MP neutral, unaffected MCP joints in 15 degrees flexion, and the DIP/PIP joints free for 4 weeks. Early dynamic splinting improves results.¹¹³

Zones VII and VIII injuries involve the wrist and forearm. Many open wounds will have associated extensor retinaculum lacerations, and a hand surgeon should repair these. Like flexor tendon injuries, these are at risk for adhesions within the synovial lining after repair. Deep stab wounds may also involve other tendons that are not apparent until proper operative exposure. Once the diagnosis is apparent, follow standard wound care protocols and call the surgeon for primary repair. If you refer the patient to a hand surgeon for repair (preferably within 1 week), close the skin and place a volar splint with 35 degrees of wrist extension and 15 degrees of MP flexion. Early dynamic splinting may lessen adhesions.

Phalangeal And Metacarpal Fractures

Metacarpal Fractures

Metacarpal fractures are generally divided into 2 groups: those involving the first metacarpal and those involving metacarpals 2 through 5. The thumb metacarpal is highly mobile in comparison to metacarpals 2 through 5. The little finger metacarpal is the most frequently fractured bone in the hand, while a thumb metacarpal fracture is relatively uncommon. Metacarpals 2 and 3 are essentially immobile, whereas metacarpals 4 and 5 have about 15-25 degrees of AP motion (observe this as you touch your little finger to thumb). Metacarpals 2 and 3 are thus considered "the fixed center of the hand," and therefore fractures of these metacarpals require anatomic reduction to ensure proper functioning. Fractures of the ring and small finger metacarpals do not require complete anatomic reduction, because their normal mobility allows for compensation.¹¹⁴

Fractures of the second through the fifth metacarpals are classified into 4 classes: head, neck, shaft, and base fractures. In general, most neck and shaft fractures, non-displaced fractures, and fractures with stable reductions may be treated nonoperatively. (See **Table 4** on page 21.) Unstable reductions, metacarpal base fractures, multiple or open metacarpal fractures, irreducible fractures, and displaced intraarticular fractures of the base and head require operative fixation.⁸

The mechanism of injury in metacarpal neck fracture is usually a direct impacting force, which almost always results in unstable fractures with some degree of volar angulation. Maintaining reduction is difficult because the deforming muscle forces prevent bones from staying

Continued on page 21

Ten Pitfalls To Avoid

1. "The patient didn't need an x-ray. I explored the wound and didn't see anything. The laceration was caused by a wood splinter and wouldn't have shown up anyway."

Sure, plain radiographs almost certainly would not have picked up the foreign body, but some providers fail to order x-rays, even in wounds with potential radio-opaque foreign bodies, such as glass! More importantly, other modalities, such as US and CT, have a good chance of picking up radio-lucent foreign bodies when the suspicion is high enough.

2. "I saw him right after he tried to unclog a spray gun that evening. He had a 2-mm wound near the DIP flexion crease of his non-dominant index finger. There was full range of motion and he was neurovascularly intact. I hate to call the "Orthopods" at night. He should have been fine until they saw him the next morning. I still can't believe his finger needed amputation."

High-pressure injection injuries to the hand often look unimpressive if seen early. The DIP and PIP flexion creases are the most easily violated areas along the flexor tendon sheath, and digit amputation is common for finger injections with delayed surgery. Consult a hand surgeon immediately from the ED for decompression, exploration, and debridement.

3. "I told the patient to find an orthopedist to have that index finger fracture reevaluated in a week or two. I even placed it in a radial gutter splint; it's not my fault he waited over a month to be seen and had a bad outcome."

Specific discharge handouts arranging timely and symptom-specific follow-up are a good practice for any ED diagnosis. Soft tissue contraction of the hand starts within a few days of hand fractures, and motion of uninvolved joints should start by that time if possible. Hand fracture treatment and rehabilitation are generally more complicated than most emergency physicians realize, so arrange early and specific follow-up for all but the most straightforward cases.

4. "I always sew up patients' hand wounds in the hallway when it's busy. Otherwise, they would be waiting hours for a bed to clear, and they really seem appreciative that I'm helping them out."

You won't do any patient a favor by missing a tendon laceration or foreign body in their wound, so wait for the open bed. At the very least, anesthetize the wound, drag a portable light over to the chair, and explore it under a bloodless field before repairing it. Patients (and your malpractice carrier) will surely appreciate it if you pick up these often subtle injuries the first time.

5. "How was I to know that laceration to his knuckle was from punching someone in the mouth? He was drunk and told the triage nurse he cut it with a knife."

Human bite wounds to the hand, including "fight-bites," are at high risk for infection. Injuries to the dorsal MP joints are commonly seen in patients involved in fisticuff activities while intoxicated. The pattern is well reported enough that you should assume it is the cause of the MP laceration, unless another mechanism is more plausible.

6. "It was an occlusional human bite wound to the hand,

but it wasn't a clenched fist injury. I washed it out and left it open. The wound didn't involve anything else, so I didn't think it was necessary to start the patient on antibiotics."

All human bite wounds to the hand warrant prophylactic antibiotics, not just clenched fist injuries or those involving underlying tendon, bone, or joints.

7. "I told the patient I didn't care if he was a guitar player, there's no way a hand surgeon is going to try and reattach your finger. The drunk guy cut off the end of his index finger just proximal to the DIP. It was his non-dominant hand and the amputation was fairly distal. I didn't even consider him to be a potential candidate for reattachment."

A single digit amputation distal to the FDS insertion is an indication for reattachment, so consult a hand surgeon from the ED in these cases. Playing guitar and other musical instruments require excellent dexterity and complete function of the non-dominant hand. Hand surgeons make case-by-case management decisions for many hand injuries based on a patient's required use of fine motor skills in their professions or hobbies.

8. "He just jammed his finger playing basketball, and I even put a finger splint on it. What's the basis of his lawsuit?"

Yes, but did you check for an acute central tendon rupture, send him for close follow-up, and warn him specifically of the possibility of delayed complications from his closed PIP injury? He took the splint off in a week and never saw a physician (that is, until one diagnosed his boutonniere deformity). Now his college basketball scholarship is in jeopardy and he has "lawyered-up." Can you say, "Failure to diagnose?"

9. "The father said the 2-year-old reached up and touched the burner with both hands. The burns were only superficial partial thickness. I told them to follow-up in 1-2 weeks with their pediatrician."

Most authorities agree that hand burns can be treated as outpatients, but only in certain instances. The above history is suspicious for either abuse and/or neglect. If a patient is going to be discharged, the home environment must be supportive, and the family must be able to adequately perform dressing changes. Arrange follow-up for these patients to provide wound checks, adequate dressing changes, and consultation by dedicated hand therapists.

10. "It was just a subungual hematoma that I trephinated. It doesn't matter if the nail plate or fold is disrupted. I work in a very busy ED and don't have time to take the nail off and repair a nail bed laceration that may or may not even be there."

Recent literature supports conservative treatment with trephination for closed subungual hematomas, although this may not be appropriate in the above case. Especially in a young female or other patients in whom cosmetic results are important. Cases in which the nail fold is disrupted or the nail plate dislodged usually require removal of the nail plate and repair of the underlying nail bed. Of note, there are no data that show trephinating closed subungual hematomas with underlying tuft fractures "converts" these to open fractures, which has classically been taught. ▲

in normal alignment. Treatment of ring and small finger metacarpal neck fractures differs from the index and middle metacarpals. As a general rule, less than 15 degrees angulation in the index and middle metacarpals, and less than 35 and 45 degrees (respectively) in the ring and small metacarpals, is acceptable. Any rotational malalignment

is unacceptable.¹¹⁷ Immobilize nondisplaced ring and small finger metacarpal neck fractures in an ulnar gutter splint. Immobilize nondisplaced index and middle finger metacarpal neck fractures with a radial gutter splint in the intrinsic plus position.

Reduce displaced ring and small finger metacarpal neck fractures using the 90-90 method in the ED, after appropriate anesthesia with a hematoma block. Flex the

Table 4. Hand Fractures.

Fracture	Treatment
Distal Phalanx:	
•Tuft, longitudinal, nondisplaced	•Hairpin splint or dorsal aluminum foam splint distal to PIP for 2-3 wks.
•Transverse shaft and irreducible fractures	•Dorsal alum. foam splint; refer early for operative reduction
•Closed Mallet fracture (dorsal base)	•DIP extension splint for 6-8 wks; refer early, some choose CRIF if > 1/3 articular surface displaced
•Displaced profundus tendon avulsion (volar base)	•Wrist to finger splint (fingers in partial flexion); refer in 5-7 days for operative reduction
Middle and Proximal Phalanges	
•Middle phalanx volar base < 40% articular surface	•Dorsal long digital splint in 60 degrees flexion for 4 wks; refer in 7 days for readjustment
•Middle phalanx volar base > 40%, Pilon fracture or single large avulsion fragment of base	•Gutter splint or dorsal long digital splint; prompt referral for dynamic traction splint or operative repair
•Nondisplaced or reducible-stable* middle phalanx fractures (most transverse fractures)	•Dorsal long digital splint (from MC to middle phalanx) and/or buddy-taping; refer 7 days
•Nondisplaced or reducible-stable* proximal phalanx fractures (most transverse fractures)	•Burkhalter 2-slab splint or buddy-taping (if very stable); refer 7 days
•Displaced, intraarticular, open, multiple, irreducible, or unstable* fractures, oblique neck fracture, significant soft tissue injury	•Immediate ED consultation if open; Burkhalter or dorsal long digital splint if promptly referring for operative repair from ED after consultation
<i>*stability = no rotational deformity or articular gap or stepoffs, coronal angulation < 5 degrees and sagittal angulation < 10 degrees</i>	
Metacarpals (excluding thumb)	
•Nondisplaced or reducible-stable* MC neck and shaft fractures	•Burkhalter splint or Gutter splint with 90 degree MP flexion and slight IP flexion; refer 5-7 days
•Reduced-unstable*, irreducible, multiple, open, or displaced intraarticular fractures of MC head or base, significant soft tissue injury	•Immediate ED consultation if open; Burkhalter or Gutter splint if promptly referring for operative repair from ED after consultation
<i>*stability = no rotational deformity, pseudo-clawing, articular stepoffs, or unacceptable sagittal/coronal angulation</i>	
Thumb Metacarpal	
•Nondisplaced or extraarticular*	•Thumb spica splint; refer for casting 5-7 days
•Intraarticular (Bennett's or Rolando's fractures), extraarticular oblique	•Thumb spica splint; ED consult and/or prompt referral for operative repair
<i>*sagittal angulation < 20 degrees acceptable</i>	

MCP joints and IP joints 90 degrees while simultaneously applying pressure in a volar direction over the metacarpal shaft, and in a dorsal direction over the flexed PIP joint. Place the patient in an ulnar gutter splint with the hand in the intrinsic plus position once reduced. Take postreduction radiographs and refer the patient to a hand surgeon. Displaced or angulated index or middle finger metacarpal neck fractures usually require anatomic reduction and surgical fixation.

Metacarpal shaft fractures differ from neck fractures, because rotational deformity and shortening of the shaft are more common and less angular deformity is acceptable. No angulation is acceptable in index and middle finger shaft fractures. In ring and small finger metacarpal shaft fractures, 10 and 20 degrees, respectively, are acceptable. All rotational deformity must be corrected.

Disposition

Discharge

The ultimate goal of the emergency physician when treating hand injuries is safe disposition, not necessarily a command of all precise surgical techniques and processes. The emergency physician needs to know which patients need inpatient admission, and which ones may be discharged with proper follow-up. Many hand injuries demand emergent consultation with a hand surgeon and possible inpatient treatment. These injuries include amputations of hands or digits that are candidates for replantation, vascular injuries, high pressure injection injuries, CMC fracture-dislocations, open metacarpals/carpal fractures, open proximal/middle phalanx fractures, complex or irreducible dislocations, bite wounds with injury to tendon, vessel or joint, clenched fist bite injuries, and high-risk hand burns.

When discharging patients, the emergency physician must ensure that the patient is properly immobilized, has adequate pain and inflammation control, and has appropriate follow-up. NSAIDs and narcotic pain medicines are both options for pain control, depending on the severity of the injury and the patient's reported level of pain. The patients should be educated on RICE techniques (rest, ice, compression, elevation) as a means to limit pain and swelling. Additionally, patients should be given tetanus or rabies prophylaxis, as indicated, before discharge, and they should be sent home with antibiotics, when warranted. Even though they may not demand immediate consultation, many patients with injuries, such as flexor tendon lacerations or thumb MC fractures, require early referral to a hand surgeon. A telephone consultation with a hand surgeon can often assure prompt follow-up and may provide valuable advice on treatment options. Recognizing the true hand emergency and providing the optimal initial treatment, without causing harm, remains the key to effectively managing individual patients and their hand problems.

Summary

Nearly all of us depend on normal hand function to make a living and seamlessly move through our daily lives and careers. Loss of hand function has a major monetary and psychological impact on these patients with significant hand injuries. As this article has made evident, hand injuries present in many different forms, each requiring specific interventions for optimal recovery. Aided by a healthy appreciation of the intricacies of hand anatomy and physiology, the practicing emergency physician should be able to identify and manage these potentially disabling injuries. The details of specific management are less important than the underlying concepts of safe practice management. Long-term sequelae, such as loss of dexterity, stiffness, and pain, will most certainly bring patients back to another doctor and, perhaps, to a lawyer. When in doubt, appropriately splinting and arranging follow-up with knowledgeable consultants is the best bet for everyone involved. ▲

References

Evidence-based medicine requires a critical appraisal of the literature based upon study methodology and number of subjects. Not all references are equally robust. The findings of a large, prospective, randomized, and blinded trial should carry more weight than a case report.

To help the reader judge the strength of each reference, pertinent information about the study, such as the type of study and the number of patients in the study, will be included in bold type following the reference, where available.

1. Redmon HA. Acute hand injuries. Emergency room management. *J Fla Med Assoc* Jul 1989;76(7):633-636.
2. Overton DT, Uehara DT. Evaluation of the injured hand. *Emerg Med Clin North Am* Aug 1993;11(3):585-600.
3. Packer GJ, Shaheen MA. Patterns of hand fractures and dislocations in a district general hospital. *J Hand Surg [Br]* Aug 1993;18(4):511-514. **(Retrospective)**
4. van Onselen EB, Karim RB, Hage JJ, et al. Prevalence and distribution of hand fractures. *J Hand Surg [Br]* Oct 2003;28(5):491-495.
5. Ljungberg E, Rosberg HE, Dahlin LB. Hand injuries in young children. *J Hand Surg [Br]* Aug 2003;28(4):376-380. **(Review, 455 young patients aged 0-6 years)**
6. Nimkin K, Spevak MR, Kleinman PK. Fractures of the hands and feet in child abuse: imaging and pathologic features. *Radiology* Apr 1997;203(1):233-236.
7. De Jonge JJ, Kingma J, van der Lei B, et al. Phalangeal fractures of the hand. An analysis of gender and age-related incidence and aetiology. *J Hand Surg [Br]* Apr 1994;19(2):168-170. **(Review, 6857 phalangeal fractures)**
8. Henry M. Fractures and dislocations of the hand. In: Rockwood CA, Green DP, Heckman JD, Bucholz RW,

eds. *Rockwood and Green's Fractures in Adults*. 5th Ed. Vol 1. Philadelphia: Lippincott Williams & Wilkins; 2001:656-748. **(Textbook chapter)**

9. Davis TR, Stothard J. Why all finger fractures should be referred to a hand surgery service: a prospective study of primary management. *J Hand Surg [Br]* Aug 1990;15(3):299-302.
10. Gaul JS, Jr. Identifiable costs and tangible benefits resulting from the treatment of acute injuries of the hand. *J Hand Surg [Am]* Sep 1987;12(5 Pt 2):966-970.
11. Johnson M, Ford M, Johansen K. Radial or ulnar artery laceration. Repair or ligate? *Arch Surg* Sep 1993;128(9):971-974; discussion 974-975.
12. Rohrbough JT, Mudge MK, Schilling RC. Overuse injuries in the elite rock climber. *Med Sci Sports Exerc* Aug 2000;32(8):1369-1372.
13. Schlenker JD, Koulis CP. Amputations and replantations. *Emerg Med Clin North Am* Aug 1993;11(3):739-753.
14. Steele MT, Tran LV, Watson WA, et al. Retained glass foreign bodies in wounds: predictive value of wound characteristics, patient perception, and wound exploration. *Am J Emerg Med* Nov 1998;16(7):627-630. **(Case series, 164 patients)**
15. Edwards SA, Harper GD, Giddins GE. Efficacy of forearm versus upper arm tourniquet for local anesthetic surgery of the hand. *J Hand Surg [Br]* Dec 2000;25(6):573-574.
16. Green DP. General Principles. In: Green DP, Hotchkiss RN, Pederson WC, eds. *Operative Hand Surgery*. Vol 1. New York: Churchill Livingstone; 1999:1-22. **(Textbook chapter)**
17. Wilgis EF. Observations on the effects of tourniquet ischemia. *J Bone Joint Surg Am* Oct 1971;53(7):1343-1346.
18. Shepard GH. Nail grafts for reconstruction. *Hand Clin* Feb 1990;6(1):79-102; discussion 103.
19. Sloan EP. Nerve injuries in the hand. *Emerg Med Clin North Am* Aug 1993;11(3):651-670.
20. Glickel SZ, Barron A, Eaton RG. Dislocations and ligament injuries in the digits. In: Green DP, Hotchkiss RN, Pederson WC, eds. *Operative Hand Surgery*. 4th Ed. Vol 1. New York: Churchill Livingstone; 1999:788-794. **(Textbook chapter)**
21. Carter PR. Injuries to the major nerves of the hand. *Emerg Med Clin North Am* May 1985;3(2):351-363.
22. Salem MZ. Simple finger tourniquet. *Br Med J* Jun 30 1973;2(5869):779.
23. Smith NC, Moncrieff NJ, Hartnell N, et al. Pseudorotation of the little finger metacarpal. *J Hand Surg [Br]* Oct 2003;28(5):395-398.
24. Alzen G, Duque-Reina D, Urhahn R, et al. [Radiographic examination of injuries in children. Clinical and legal considerations about indications]. *Dtsch Med Wochenschr* Mar 6 1992;117(10):363-367.
25. American College of Radiology, Expert Panel on Musculoskeletal Imaging. Acute hand and wrist trauma. (ACR appropriateness criteria). Reston (VA). American College of Radiology (ACR). 2001:7p. **(Practice guideline)**
26. Robson AK, Bloom PA. Suturing of digital lacerations: digital block or local infiltration? *Ann R Coll Surg Engl* Nov 1990;72(6):360-361. **(Prospective, 62 patients)**
27. Knoop K, Trott A, Syverud S. Comparison of digital versus metacarpal blocks for repair of finger injuries. *Ann Emerg Med* Jun 1994;23(6):1296-1300.
28. Bartfield JM, Gennis P, Barbera J, et al. Buffered versus plain lidocaine as a local anesthetic for simple laceration repair. *Ann Emerg Med* Dec 1990;19(12):1387-1389. **(Randomized controlled trial, 91 adult patients with simple linear lacerations)**
29. Denkler K. A comprehensive review of epinephrine in the finger: to do or not to do. *Plast Reconstr Surg* Jul 2001;108(1):114-124.
30. Wilhelmi BJ, Blackwell SJ, Miller JH, et al. Do not use epinephrine in digital blocks: myth or truth? *Plast Reconstr Surg* Feb 2001;107(2):393-397. **(Prospective, double blinded, randomized controlled (epi/lido vs. plain lido) study of 60 digital blocks for posttraumatic wounds and elective conditions)**
31. Sylaidis P, Logan A. Digital blocks with adrenaline. An old dogma refuted. *J Hand Surg [Br]* Feb 1998;23(1):17-19.
32. Wilhelmi BJ, Blackwell SJ, Miller J, Mancoll JS, Phillips LG. Epinephrine in digital blocks: revisited. *Ann Plast Surg* Oct 1998;41(4):410-414. **(Systematic review and case series of 23 digital blocks containing epinephrine without complications)**
33. Burnham PJ. Regional block anesthesia for surgery of the fingers and thumb. *Ind Med Surg* Feb 1958;27(2):67-69 **(Descriptive; 93 patients, 1:200,000 epinephrine used, no complications)**
34. Johnson HA. Infiltration with epinephrine and local anesthetic mixture in the hand. *JAMA* Jun 12 1967;200(11):990-991. **(Descriptive; 98 finger blocks using epinephrine, no complications)**
35. Steinberg MD, Block P. The use and abuse of epinephrine in local anesthetics. *J Am Podiatry Assoc* Sep 1971;61(9):341-343. **(Descriptive, lidocaine with epinephrine in 200,000 foot/toe injections without necrosis/gangrene)**
36. Furia JP, Alioto RJ, Marquardt JD. The efficacy and safety of the hematoma block for fracture reduction in closed, isolated fractures. *Orthopedics* May 1997;20(5):423-426.
37. Burkhalter WE. Closed treatment of hand fractures. *J Hand Surg [Am]* Mar 1989;14(2 Pt 2):390-393.
38. American College of Emergency Physicians: Clinical

- policy for the initial approach to patients presenting with penetrating extremity trauma. *Ann Emerg Med* May 1999;33(5):612-636. **(Practice guideline)**
39. Valente JH, Forti RJ, Freundlich LF, et al. Wound irrigation in children: saline solution or tap water? *Ann Emerg Med* May 2003;41(5):609-616. **(Prospective trial)**
 40. Dire DJ, Welsh AP. A comparison of wound irrigation solutions used in the emergency department. *Ann Emerg Med* Jun 1990;19(6):704-708.
 41. Roberts AH, Roberts FE, Hall RI, et al. A prospective trial of prophylactic povidone iodine in lacerations of the hand. *J Hand Surg [Br]* Oct 1985;10(3):370-374. **(Prospective trial)**
 42. Lammers RL, Fourre M, Callahan ML, et al. Effect of povidone-iodine and saline soaking on bacterial counts in acute, traumatic, contaminated wounds. *Ann Emerg Med* Jun 1990;19(6):709-714.
 43. Quinn J, Cummings S, Callahan M, et al. Suturing versus conservative management of lacerations of the hand: randomised controlled trial. *BMJ* Aug 10 2002;325(7359):299. **(Randomized controlled trial, 91 patients)**
 44. Cummings P, Del Beccaro MA. Antibiotics to prevent infection of simple wounds: a meta-analysis of randomized studies. *Am J Emerg Med* Jul 1995;13(4):396-400. **(Meta-analysis)**
 45. Grossman JA, Adams JP, Kunec J. Prophylactic antibiotics in simple hand lacerations. *JAMA* Mar 13 1981;245(10):1055-1056.
 46. Kaiser CW, Slowick T, Spurling KP, et al. Retained foreign bodies. *J Trauma* Jul 1997;43(1):107-111.
 47. Avner JR, Baker MD. Lacerations involving glass. The role of routine roentgenograms. *Am J Dis Child* May 1992;146(5):600-602.
 48. Gron P, Andersen K, Vraa A. Detection of glass foreign bodies by radiography. *Injury* Nov 1986;17(6):404-406. **(Case reports, 26 patients)**
 49. Courter BJ. Radiographic screening for glass foreign bodies--what does a "negative" foreign body series really mean? *Ann Emerg Med* Sep 1990;19(9):997-1000.
 50. Wendt JR, Ackley SM. Vascular complications of a foreign body in the hand of an asymptomatic patient. *Ann Plast Surg* Jan 1995;34(1):92-94. **(Case reports)**
 51. Humzah D, Moss AL. Delayed digital nerve transection as a result of a retained foreign body. *J Accid Emerg Med* Dec 1994;11(4):261-262. **(Case reports)**
 52. Graham DD, Jr. Ultrasound in the emergency department: detection of wooden foreign bodies in the soft tissues. *J Emerg Med* Jan 2002;22(1):75-79.
 53. Turner J, Wilde CH, Hughes KC, et al. Ultrasound-guided retrieval of small foreign objects in subcutaneous tissue. *Ann Emerg Med* Jun 1997;29(6):731-734.
 54. Gilbert FJ, Campbell RS, Bayliss AP. The role of ultrasound in the detection of non-radiopaque foreign bodies. *Clin Radiol* Feb 1990;41(2):109-112.
 55. Manthey DE, Storrow AB, Milbourn JM, et al. Ultrasound versus radiography in the detection of soft-tissue foreign bodies. *Ann Emerg Med* Jul 1996;28(1):7-9. **(Randomized controlled trial, evaluating 120 chicken thighs for foreign bodies)**
 56. Bray PW, Mahoney JL, Campbell JP. Sensitivity and specificity of ultrasound in the diagnosis of foreign bodies in the hand. *J Hand Surg [Am]* Jul 1995;20(4):661-666.
 57. McGuckin JF Jr, Akhtar N, Ho VT, et al. CT and MR evaluation of a wooden foreign body in an in vitro model of the orbit. *AJNR Am J Neuroradiol* Jan 1996;17(1):129-133.
 58. Griego RD, Rosen T, Orengo IF, et al. Dog, cat, and human bites: a review. *J Am Acad Dermatol* Dec 1995;33(6):1019-1029. **(Review)**
 59. Goldstein EJ. Management of human and animal bite wounds. *J Am Acad Dermatol* Dec 1989;21(6):1275-1279.
 60. Talan DA, Citron DM, Abrahamian FM, et al. Bacteriologic analysis of infected dog and cat bites. Emergency Medicine Animal Bite Infection Study Group. *N Engl J Med* Jan 14 1999;340(2):85-92.
 61. Medeiros I, Saconato H. Antibiotic prophylaxis for mammalian bites. *Cochrane Database Syst Rev* 2003(2): CD001738. **(Cochrane review)**
 62. Brook I. Human and animal bite infections. *J Fam Pract* Jun 1989;28(6):713-718.
 63. Talan DA, Abrahamian FM, Moran GJ, Citron DM, Tan JO, Goldstein EJ. Clinical presentation and bacteriologic analysis of infected human bites in patients presenting to emergency departments. *Clin Infect Dis* Dec 1 2003;37(11):1481-1489. **(Multicenter prospective study, 50 patients with infected human bites)**
 64. Zubowicz VN, Gravier M. Management of early human bites of the hand: a prospective randomized study. *Plast Reconstr Surg* Jul 1991;88(1):111-114. **(Prospective randomized study)**
 65. Zook EG, Miller M, Van Beek AL, et al. Successful treatment protocol for canine fang injuries. *J Trauma* Mar 1980;20(3):243-247.
 66. Kaplan MM, Cohen D, Koprowski H, et al. Studies on the local treatment of wounds for the prevention of rabies. *Bull World Health Organ* 1962;26:765-775.
 67. Goldstein EJ. Bite wounds and infection. *Clin Infect Dis* Mar 1992;14(3):633-638. **(Review)**
 68. Schoo MJ, Scott FA, Boswick JA, Jr. High-pressure injection injuries of the hand. *J Trauma* Mar 1980;20(3):229-238.
 69. Gutowski KA, Chu J, Choi M, et al. High-pressure hand injection injuries caused by dry cleaning solvents: case

reports, review of the literature, and treatment guidelines. *Plast Reconstr Surg* Jan 2003;111(1):174-177. **(Case reports, review)**

70. Sirio CA, Smith JS Jr, Graham WP 3rd. High-pressure injection injuries of the hand. A review. *Am Surg* Dec 1989;55(12):714-718. **(Case reports, review)**
71. Hayes CW, Pan HC. High-pressure injection injuries to the hand. *South Med J* Dec 1982;75(12):1491-1498,1516.
72. Lewis RC Jr. High-compression injection injuries to the hand. *Emerg Med Clin North Am* May 1985;3(2):373-381.
73. Grabb WC. Management of nerve injuries in the forearm and hand. *Orthop Clin North Am* Nov 1970;1(2):419-431.
74. Muller H, Grubel G. Long-term results of peripheral nerve sutures: a comparison of micro-macrosurgical technique. *Adv Neurosurgery* 1981;9:381-387.
75. Kleinert HE, Griffin JM. Technique of nerve anastomosis. *Orthop Clin North Am* Oct 1973;4(4):907-915. **(Review)**
76. Omer GE Jr. Evaluation of the extremity with peripheral nerve injury and timing for nerve suture. *Instr Course Lect* 1984;33:463-486.
77. Drucek C 3rd. Emergency department treatment of hand burns. *Emerg Med Clin North Am* Aug 1993;11(3):797-809.
78. Pruitt BA. Burns of the upper extremity. Epidemiology and general considerations. *Major Probl Clin Surg* 1976;19:1-15.
79. Hentz VR. Burns of the hand. Thermal, chemical, and electrical. *Emerg Med Clin North Am* May 1985;3(2):391-403.
80. Sheridan RL, Hurley J, Smith MA, et al. The acutely burned hand: management and outcome based on a ten-year experience with 1047 acute hand burns. *J Trauma* Mar 1995;38(3):406-411. **(Review, 1047 acute hand burns in 659 patients)**
81. Smith MA, Munster AM, Spence RJ. Burns of the hand and upper limb--a review. *Burns* Sep 1998;24(6):493-505. **(Review)**
82. Hart RG, Kleinert HE. Fingertip and nail bed injuries. *Emerg Med Clin North Am* Aug 1993;11(3):755-765. **(Review)**
83. Jackson EA. The V-Y plasty in the treatment of fingertip amputations. *Am Fam Physician* Aug 1 2001;64(3):455-458.
84. El-Hussaen A. Fingertip and nail bed injuries. Postgraduate Medicine. 1995;98(5):217-236.
85. Simon RR, Wolgin M. Subungual hematoma: association with occult laceration requiring repair. *Am J Emerg Med* Jul 1987;5(4):302-304. **(Case series, 47 patients)**
86. Seaberg DC, Angelos WJ, Paris PM. Treatment of subungual hematomas with nail trephination: a prospective study. *Am J Emerg Med* May 1991;9(3):209-210.
87. Roser SE, Gellman H. Comparison of nail bed repair versus nail trephination for subungual hematomas in children. *J Hand Surg [Am]* Nov 1999;24(6):1166-1170.
88. Brown RE. Acute nail bed injuries. *Hand Clin* Nov 2002;18(4):561-575.
89. Abouzahr MK, Poblete JV. Irreducible dorsal dislocation of the distal interphalangeal joint: case report and literature review. *J Trauma* Apr 1997;42(4):743-745. **(Case reports)**
90. Benke GJ, Stableforth PG. Injuries of the proximal interphalangeal joint of the fingers. *Hand* Oct 1979;11(3):263-268.
91. Elson RA. Rupture of the central slip of the extensor hood of the finger. A test for early diagnosis. *J Bone Joint Surg Br* Mar 1986;68(2):229-231.
92. Freiberg A, Pollard BA, Macdonald MR, et al. Management of proximal interphalangeal joint injuries. *J Trauma* Mar 1999;46(3):523-528. **(Review)**
93. Stern PJ, Lee AF. Open dorsal dislocations of the proximal interphalangeal joint. *J Hand Surg [Am]* May 1985;10(3):364-370.
94. Inoue G, Maeda N. Irreducible palmar dislocation of the proximal interphalangeal joint of the finger. *J Hand Surg [Am]* Mar 1990;15(2):301-304. **(Case reports)**
95. Stener B. Displacement of the ruptured ulnar collateral ligament of the metacarpophalangeal joint of the thumb. A clinical and anatomical study. *J Bone Joint Surg Am* 1972;44(B):869-879.
96. Heyman P, Gelberman RH, Duncan K, et al. Injuries of the ulnar collateral ligament of the thumb metacarpophalangeal joint. Biomechanical and prospective clinical studies on the usefulness of valgus stress testing. *Clin Orthop* Jul 1993(292):165-171. **(Clinical trial)**
97. Palmer AK, Louis DS. Assessing ulnar instability of the metacarpophalangeal joint of the thumb. *J Hand Surg [Am]* Nov 1978;3(6):542-546.
98. Newland CC. Gamekeeper's thumb. *Orthop Clin North Am* Jan 1992;23(1):41-48. **(Review)**
99. Coonrad RW, Goldner JL. A study of the pathological findings and treatment in soft-tissue injury of the thumb metacarpophalangeal joint. With a clinical study of the normal range of motion in one thousand thumbs and a study of post mortem findings of ligamentous structures in relation to function. *J Bone Joint Surg Am* Apr 1968;50(3):439-451.
100. Helm RH. Hand function after injuries to the collateral ligaments of the metacarpophalangeal joint of the thumb. *J Hand Surg [Br]* Jun 1987;12(2):252-255.
101. Durham JW, Khuri S, Kim MH. Acute and late radial collateral ligament injuries of the thumb metacarpophalangeal joint. *J Hand Surg [Am]* Mar 1993;18(2):232-237.

102. Gurland M. Carpometacarpal joint injuries of the fingers. *Hand Clin* Nov 1992;8(4):733-744.
103. Stone JF, Davidson JS. The role of antibiotics and timing of repair in flexor tendon injuries of the hand. *Ann Plast Surg* Jan 1998;40(1):7-13. **(Retrospective, 140 patients)**
104. Gelberman RH, Siegel DB, Woo SL, et al. Healing of digital flexor tendons: importance of the interval from injury to repair. A biomechanical, biochemical, and morphological study in dogs. *J Bone Joint Surg Am* Jan 1991;73(1):66-75.
105. Kleinert HE, Smith DJ. Primary and secondary repairs of flexor and extensor tendon injuries. In: Jupiter JB, ed. *Flynn's Hand Surgery*. 4th Ed. Baltimore: Williams & Wilkins; 1991:241-261. **(Textbook chapter)**
106. Steinberg DR. Acute flexor tendon injuries. *Orthop Clin North Am* Jan 1992;23(1):125-140.
107. McCarthy DM, Boardman ND 3rd, Tramaglini DM, et al. Clinical management of partially lacerated digital flexor tendons: a survey [corrected] of hand surgeons. *J Hand Surg [Am]* Mar 1995;20(2):273-275. **(Survey, 591/1000 respondents)**
108. Erhard L, Zobitz ME, Zhao C, et al. Treatment of partial lacerations in flexor tendons by trimming. A biomechanical in vitro study. *J Bone Joint Surg Am* Jun 2002;84-A(6):1006-1012.
109. Schlenker JD, Lister GD, Kleinert HE. Three complications of untreated partial laceration of flexor tendon--entrapment, rupture, and triggering. *J Hand Surg [Am]* Jul 1981;6(4):392-398.
110. Hart RG, Uehara DT, Kutz JE. Extensor tendon injuries of the hand. *Emerg Med Clin North Am* Aug 1993;11(3):637-649. **(Review)**
111. Blair WF, Steyers CM. Extensor tendon injuries. *Orthop Clin North Am* Jan 1992;23(1):141-148.
112. Kleinert HE, Verdan C. Report of the Committee on Tendon Injuries (International Federation of Societies for Surgery of the Hand). *J Hand Surg [Am]* Sep 1983;8(5 Pt 2):794-798.
113. Rockwell WB, Butler PN, Byrne BA. Extensor tendon: anatomy, injury, and reconstruction. *Plast Reconstr Surg* Dec 2000;106(7):1592-1603; quiz 1604, 1673. **(Review)**
114. Bowman SH, Simon RR. Metacarpal and phalangeal fractures. *Emerg Med Clin North Am* Aug 1993;11(3):671-702.
115. Golden GT, David D, Smith TE, et al. Fractures of the phalanges and metacarpals: An analysis of 555 fractures. *JACEP* 1977;6:79-84.
116. Hastings H 2nd, Carroll C 4th. Treatment of closed articular fractures of the metacarpophalangeal and proximal interphalangeal joints. *Hand Clin* Aug 1988;4(3):503-527. **(Review, 134 closed articular fractures of the MCP and PIP joints)**
117. Ford DJ, Ali MS, Steel WM. Fractures of the fifth metacarpal neck: is reduction or immobilisation necessary? *J Hand Surg [Br]* May 1989;14(2):165-167.
118. Pelligrini VD Jr. Fractures at the base of the thumb. *Hand Clin* 1988;4(1):87-102. **(Review)**
119. Foster RJ, Hastings H 2nd. Treatment of Bennett, Rolando, and vertical intraarticular trapezial fractures. *Clin Orthop* Jan 1987(214):121-129.
120. Shewring DJ, Thomas RH. Avulsion fractures from the base of the proximal phalanges of the fingers. *J Hand Surg [Br]* Feb 2003;28(1):10-14.
121. Boles CA, Daniel WW, Adams BD, et al. Hand and wrist. *Radiol Clin North Am* Mar 1995;33(2):319-354. **(Review)**
122. Al Qattan MM, Hashem F, Helmi A. Irreducible tuft fractures of the distal phalanx. *J Hand Surg [Br]* Feb 2003;28(1):18-20. **(Case reports, 2 unique tuft fractures of the distal phalanx)**
123. DaCruz DJ, Slade RJ, Malone W. Fractures of the distal phalanges. *J Hand Surg [Br]* Aug 1988;13(3):350-352. **(Prospective study, 110 patients with fractures of the distal phalanx)**

Physician CME Questions

17. All the following amputations are indications for replantation EXCEPT:
 - a. multiple digits
 - b. any amputation in a child
 - c. single digital amputation distal to the FDP insertion
 - d. thumb amputation
 - e. mid-palmar amputation
18. Identify the false statement below in regards to wound foreign bodies of the hand:
 - a. Inspection and exploration of wounds is inadequate to completely rule out the presence of foreign bodies
 - b. Glass foreign bodies > 2 mm can be generally excluded with x-rays
 - c. CT is generally insensitive in detecting foreign bodies
 - d. Lack of foreign body sensation is not reliable to rule out the presence of foreign bodies
 - e. Glass is the most commonly reported foreign body in hand wounds

19. Which of the following is an acceptable method to apply a splint on a patient with a metacarpal shaft fracture, if you are referring to an orthopedist?
 - a. Wrist 20 degrees flexion, MPs and PIPs extended
 - b. Wrist neutral, MPs 20 degrees flexion, IPs extended
 - c. Wrist neutral, MPs 30 degrees flexion, IPs extended
 - d. Wrist 20 degrees extension, MPs 20 degrees flexion, PIPs extended
 - e. Wrist 30 degrees extension, MPs 90 degrees flexion, IPs extended or free
20. The best way to reduce a simple dorsal thumb MP dislocation is to:
 - a. Flex and adduct the MP joint with thumb IP and wrist flexion, then apply dorsal pressure to the proximal phalanx base
 - b. Axial traction of the thumb phalanx
 - c. Extend the MP joint with axial traction and apply a volar pressure to the phalanx
 - d. Flex the MP joint with wrist in extension and apply volar pressure to the thumb MC
 - e. Call the hand surgeon; these are usually irreducible, and you may cause volar plate injury
21. The typical patient suffering a high-pressure injection injury to the hand has all the following characteristics except:
 - a. Male
 - b. Adult
 - c. Injured attempting to dislodge a blockage from a piece of high-pressure equipment
 - d. Injury occurs on the dominant hand
 - e. Substance injected is related to prognosis
22. When evaluating a patient with a subungual hematoma, which of the following is an indication for nail removal and exploration?
 - a. Age < 12
 - b. Subungual hematoma > 25% of nail surface
 - c. Subungual hematoma > 50% of nail surface
 - d. Disruption of the nail fold
 - e. Fracture of the distal phalanx
23. Prophylactic antibiotics are indicated in all the following hand wounds except:
 - a. Simple, sutured wounds
 - b. Dog or cat bites
 - c. Clenched fist injuries
 - d. Human bites
 - e. Open metacarpal fractures
24. Which of the following techniques can help limit the pain of a digit block?
 - a. Quick injection
 - b. 23-gauge needle
 - c. Larger syringe (10-20cc)
 - d. Buffering lidocaine with sodium bicarbonate
 - e. Cooling the anesthetic
25. Which of the following is the most commonly dislocated joint on the hand:
 - a. DIP
 - b. PIP
 - c. MCP
 - d. Thumb IP
 - e. CMC
26. Which of the following answers is true concerning "Skiers" or "Gamekeeper's Thumb"?
 - a. Named for common injury to soccer players at the goalie position
 - b. Always associated with a Stener lesion
 - c. Injury to the radial collateral ligament
 - d. Operative repair is generally required if a Stener lesion is verified
 - e. Fracture of the proximal phalanx of the thumb
27. Physical examination findings concerning for nerve injury include:
 - a. 2 point discrimination of 4 mm at the fingertip
 - b. Normal sweating distal to the site of injury
 - c. Failure of normal wrinkling of the skin after soaking in warm water for 30 minutes
 - d. 2 point discrimination of 8 mm in injured and unaffected fingertips
28. A positive Froment's sign shows weakness of the adductor pollicis and indicates:
 - a. Radial nerve palsy
 - b. Median nerve palsy
 - c. Ulnar nerve palsy
 - d. Ulnar collateral ligament injury of the thumb
 - e. Radial collateral ligament injury of the thumb
29. The primary function of the flexor digitorum profundus is flexion of which joint?
 - a. PIP
 - b. DIP
 - c. MP
 - d. Wrist
30. What degree of angulation is acceptable for a metacarpal shaft fracture of the long finger:
 - a. None
 - b. 10 degrees
 - c. 20 degrees
 - d. 30 degrees
 - e. 40 degrees

31. The evidence is clear that lidocaine with epinephrine is contraindicated in digital blocks:
- True
 - False
32. A "swan-neck" deformity describes a digit in which position:
- Flexion of the DIP, hyperextension of the PIP
 - Extension of the PIP, hyperextension of the DIP
 - Flexion of the PIP, hyperextension of the PIP
 - Flexion of the DIP, hyperflexion of the PIP

Coming in Future Issues:

Wound Care • Street Drugs • Stroke

Class Of Evidence Definitions

Each action in the clinical pathways section of *Emergency Medicine Practice* receives a score based on the following definitions.

Class I

- Always acceptable, safe
- Definitely useful
- Proven in both efficacy and effectiveness

Level of Evidence:

- One or more large prospective studies are present (with rare exceptions)
- High-quality meta-analyses
- Study results consistently positive and compelling

Class II

- Safe, acceptable
- Probably useful

Level of Evidence:

- Generally higher levels of evidence
- Non-randomized or retrospective studies: historic, cohort, or case-control studies
- Less robust RCTs
- Results consistently positive

Class III

- May be acceptable
- Possibly useful
- Considered optional or alternative treatments

Level of Evidence:

- Generally lower or intermediate levels of evidence

- Case series, animal studies, consensus panels
- Occasionally positive results

Indeterminate

- Continuing area of research
- No recommendations until further research

Level of Evidence:

- Evidence not available
- Higher studies in progress
- Results inconsistent, contradictory
- Results not compelling

Significantly modified from: The Emergency Cardiovascular Care Committees of the American Heart Association and representatives from the resuscitation councils of ILCOR: How to Develop Evidence-Based Guidelines for Emergency Cardiac Care: Quality of Evidence and Classes of Recommendations; also: Anonymous. Guidelines for cardiopulmonary resuscitation and emergency cardiac care. Emergency Cardiac Care Committee and Subcommittees, American Heart Association. Part IX. Ensuring effectiveness of community-wide emergency cardiac care. *JAMA* 1992;268(16):2289-2295.

Physician CME Information

This CME enduring material is sponsored by Mount Sinai School of Medicine and has been planned and implemented in accordance with the Essentials and Standards of the Accreditation Council for Continuing Medical Education. Credit may be obtained by reading each issue and completing the printed post-tests administered in December and June or online single-issue post-tests administered at EMPractice.net.

Target Audience: This enduring material is designed for emergency medicine physicians.

Needs Assessment: The need for this educational activity was determined by a survey of medical staff, including the editorial board of this publication; review of morbidity and mortality data from the CDC, AHA, NCHS, and ACEP; and evaluation of prior activities for emergency physicians.

Date of Original Release: This issue of *Emergency Medicine Practice* was published February 15, 2005. **This activity is eligible for CME credit through February 1, 2008.** The latest review of this material was February 9, 2005.

Discussion of Investigational Information: As part of the newsletter, faculty may be presenting investigational information about pharmaceutical products that is outside Food and Drug Administration approved labeling. Information presented as part of this activity is intended solely as continuing medical education and is not intended to promote off-label use of any pharmaceutical product. **Disclosure of Off-Label Usage:** This issue of *Emergency Medicine Practice* discusses no off-label use of any pharmaceutical product.

Faculty Disclosure: In compliance with all ACCME Essentials, Standards, and Guidelines, all faculty for this CME activity were asked to complete a full disclosure statement. The information received is as follows: Dr. Harrison, Dr. Holland, Dr. Perron, and Dr. Jagoda report no significant financial interest or other relationship with the manufacturer(s) of any commercial product(s) discussed in this educational presentation.

Accreditation: Mount Sinai School of Medicine is accredited by the Accreditation Council for Continuing Medical Education to sponsor continuing medical education for physicians.

Credit Designation: Mount Sinai School of Medicine designates this educational activity for up to 4 hours of Category 1 credit toward the AMA Physician's Recognition Award. Each physician should claim only those hours of credit actually spent in the educational activity. *Emergency Medicine Practice* is approved by the American College of Emergency Physicians for 48 hours of ACEP Category 1 credit (per annual subscription). *Emergency Medicine Practice* has been approved by the American Academy of Family Physicians as having educational content acceptable for Prescribed credit. Term of approval covers issues published within one year from the distribution date of July 1, 2004. This issue has been reviewed and is acceptable for up to 4 Prescribed credits. Credit may be claimed for one year from the date of this issue. *Emergency Medicine Practice* has been approved for 48 Category 2-B credit hours by the American Osteopathic Association.

Earning Credit: Two Convenient Methods

- **Print Subscription Semester Program:** Paid subscribers with current and valid licenses in the United States who read all CME articles during each *Emergency Medicine Practice* six-month testing period, complete the post-test and the CME Evaluation Form distributed with the December and June issues, and return it according to the published instructions are eligible for up to 4 hours of Category 1 credit toward the AMA Physician's Recognition Award (PRA) for each issue. You must complete both the post-test and CME Evaluation Form to receive credit. Results will be kept confidential. CME certificates will be delivered to each participant scoring higher than 70%.
- **Online Single-Issue Program:** Paid subscribers with current and valid licenses in the United States who read this *Emergency Medicine Practice* CME article and complete the online post-test and CME Evaluation Form at EMPractice.net are eligible for up to 4 hours of Category 1 credit toward the AMA Physician's Recognition Award (PRA). You must complete both the post-test and CME Evaluation Form to receive credit. Results will be kept confidential. CME certificates may be printed directly from the Web site to each participant scoring higher than 70%.

Emergency Medicine Practice is not affiliated with any pharmaceutical firm or medical device manufacturer.

Publisher: Robert Williford. **Executive Editor:** Cheryl Strauss. **Research Editors:** Ben Abella, MD, University of Chicago; Richard Kwun, MD, Mount Sinai School of Medicine.

Direct all editorial or subscription-related questions to EB Practice, LLC: 1-800-249-5770 • Fax: 1-770-500-1316 • Non-U.S. subscribers, call: 1-678-366-7933

EB Practice, LLC • 305 Windlake Court • Alpharetta, GA 30022

E-mail: emp@empractice.net • Web Site: EMPractice.net

Emergency Medicine Practice (ISSN 1524-1971) is published monthly (12 times per year) by EB Practice, LLC, 305 Windlake Court, Alpharetta, GA 30022. Opinions expressed are not necessarily those of this publication. Mention of products or services does not constitute endorsement. This publication is intended as a general guide and is intended to supplement, rather than substitute, professional judgment. It covers a highly technical and complex subject and should not be used for making specific medical decisions. The materials contained herein are not intended to establish policy, procedure, or standard of care. *Emergency Medicine Practice* is a trademark of EB Practice, LLC. Copyright ©2005 EB Practice, LLC. All rights reserved. No part of this publication may be reproduced in any format without written consent of EB Practice, LLC. Subscription price: \$299, U.S. funds. (Call for international shipping prices.)