



Original Contribution

Pulseless electrical activity in pulmonary embolism treated with thrombolysis (from the “PEAPETT” study)



Mohsen Sharifi, MD^{a,b,*}, Jeremy Berger, DO^b, Paul Beeston, DO^c, Curt Bay, PhD^b, Zoltan Vajo, MD^a, Seyed Javadpoor, MD^a, for the “PEAPETT” investigators

^a Arizona Cardiovascular Consultants & Vein Clinic, Mesa, AZ

^b A.T. Still University, Mesa, AZ

^c Team Health West, Mesa, AZ

ARTICLE INFO

Article history:

Received 15 April 2016

Received in revised form 7 June 2016

Accepted 29 June 2016

ABSTRACT

Objective: Pulseless electrical activity (PEA) during cardiac arrest portends a poor prognosis. There is a paucity of data in the use of thrombolytic therapy in PEA and cardiopulmonary arrest due to confirmed pulmonary embolism (PE). We evaluated the outcome of low-dose systemic thrombolysis with tissue plasminogen activator (tPA) in patients presenting with PEA due to PE.

Methods: During a 34-month period, we treated 23 patients with PEA and cardiopulmonary arrest due to confirmed massive PE. All patients received 50 mg of tPA as intravenous push in 1 minute while cardiopulmonary resuscitation was ongoing. The time from initiation of cardiopulmonary resuscitation to administration of tPA was 6.5 ± 2.1 minutes.

Results: Return of spontaneous circulation occurred in 2 to 15 minutes after tPA administration in all but 1 patient. There was no minor or major bleeding despite chest compression. Of the 23 patients, 2 died in the hospital, and at 22 ± 3 months of follow-up, 20 patients (87%) were still alive. The right ventricular/left ventricular ratio and pulmonary artery systolic pressure dropped from 1.79 ± 0.27 and 58.10 ± 7.99 mm Hg on admission to 1.16 ± 0.13 and 40.25 ± 4.33 mm Hg within 48 hours, respectively ($P < .001$ for both comparisons). There was no recurrent venous thromboembolism or bleeding during hospitalization or at follow-up.

Conclusion: Rapid administration of 50 mg of tPA is safe and effective in restoration of spontaneous circulation in PEA due to massive PE leading to enhanced survival and significant reduction in pulmonary artery pressures.

© 2016 Elsevier Inc. All rights reserved.

1. Introduction

1.1. Background

Pulseless electrical activity (PEA) during cardiac arrest is an ominous sign with a high mortality rate [1–3]. Administration of thrombolytics in undifferentiated PEA has not led to a survival benefit in randomized trials [2,3]. It has been estimated that massive pulmonary embolism (PE) accounts for 8% to 13% of unexplained cardiac arrests [4,5]. The current Advanced Cardiac Life Support and American Heart Association guidelines suggest that thrombolytics should be considered for cardiac arrest due to presumed PE [6,7]. However, there is no uniform consensus on the type, dose, duration, timing, and method of administration of the thrombolytic agent in this setting. A significant paucity of data is available on the efficacy and safety of thrombolytic therapy in cardiopulmonary arrest in confirmed PE.

1.2. Goals of this investigation

The present study was, therefore, undertaken to assess the effects of low dose tissue plasminogen activator (tPA) on the clinical and echocardiographic outcomes of patients who had presented with PEA and cardiopulmonary arrest due to confirmed PE.

2. Materials and methods

2.1. Study design and setting

The Pulseless Electrical Activity due to Pulmonary Embolism Treated with Thrombolysis study was a single-center report of 23 consecutive patients on whom our group was consulted. They had all developed cardiopulmonary arrest with development of PEA and had received cardiopulmonary resuscitation (CPR) due to massive PE. Because our group was consulted for their care, their information was entered in our office electronic medical record shortly after the index encounter thereby allowing for their subsequent identification and follow up. This cohort was retrospectively identified through our office electronic medical

* Corresponding author at: Arizona Cardiovascular Consultants & Vein Clinic, 3850 E. Baseline Ave, Building 1, Suite 102, Mesa, AZ 85206. Tel.: +1 480 924 0006; fax: +1 480 924 0579.
E-mail address: seyedmohsenharifi@yahoo.com (M. Sharifi).

record and followed in a prospective fashion for development of clinical and echocardiographic outcomes. The study was approved by the institutional review board of A.T. Still University. Informed written consent was obtained from all surviving patients for the observational follow-up. The surviving patients were seen in the office within 3 weeks after discharge and every 6 months thereafter. All patients underwent a venous duplex scan of the lower extremities before the second office visit and at any time if suspicion of deep venous thrombosis (DVT) was raised. If PE was suspected, objective testing would be performed by pulmonary computed tomographic (CT) angiography or ventilation/perfusion scintigraphic scanning.

2.2. Diagnosis of PE and outcome measures

Cardiopulmonary arrest developed in 17 patients who were in the emergency department (ED), 2 patients in the intensive care unit, 1 patient on the floor, and 3 patients in the radiology department. In 20 patients, PE was diagnosed by CT pulmonary angiography (Fig. 1). Of these patients, 16 were diagnosed with PE before administration of tPA; and 4, after administration of tPA. The latter group completed their CT pulmonary angiography within the first 28 hours after receiving thrombolysis. In the 3 remaining patients, large thrombus was identified in the right heart based on point-of-care echocardiography (Video 1 in the online version at <http://dx.doi.org/10.1016/j.ajem.2016.06.094>). The patients were prospectively followed up for a mean of 22 ± 3 months. Initial echocardiography was done in all within the first 3 hours after suspicion for PE was raised. All patients underwent a follow-up echocardiography within 2 days postthrombolysis. Pulmonary artery systolic pressure (PASP) was estimated from the tricuspid valve regurgitant jet velocity using the modified Bernoulli equation as previously described [8]. *Right ventricular enlargement* was defined as a right ventricle/left ventricle (RV/LV) ratio of greater than 0.9 by echocardiography (maximum dimension from apical four chamber view). The patients were evaluated at least daily while in the hospital, within 3 weeks of discharge, and every 6 months thereafter. *Major bleeding* was defined as death due to bleeding, intracerebral hemorrhage, any bleeding requiring transfusion, a drop of greater than 2 g/dL of hemoglobin, or intraocular or retroperitoneal bleeding. Any other bleeding was considered as minor.

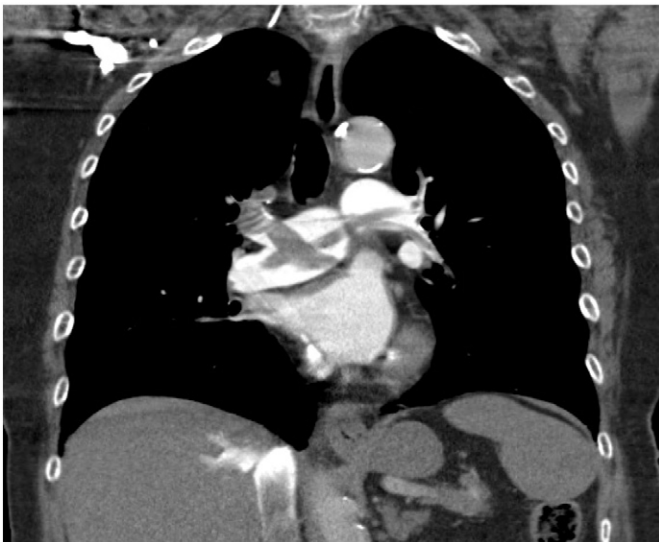

Fig. 1. A representative example of a CT pulmonary angiogram demonstrating extensive bilateral and saddle PE in the coronal plane.

2.3. Treatment approach

All patients received 50 mg of tPA (Activase; Genetech, Inc, San Francisco, CA) while CPR was ongoing. It was given in 1 minute by intravenous (IV) push followed by administration of 10 mL of saline. In the ED, tPA was kept at site in 100 mg bottles which were readily available for use. It was mixed with 100 mL of sterile water, and half of it was drawn into a 50-mL syringe. For use in intensive care unit or floors, a “stat call” was made to the respective floor pharmacy leading to its immediate preparation and delivery. Subsequently, between 2000 and 5000 of heparin was given as bolus, and the patient started on an initial maintenance drip of heparin at 10 U/kg per hour. This dose was not weight adjusted and solely based on an empiric approach to deliver a low-heparin bolus. Subsequent heparin dosing was given by changing the maintenance dose to keep the activated partial thromboplastin time (aPTT) between 60 and 100 seconds. No bolus was given for the subsequent adjustment of the aPTT. Determination of aPTT was obtained every 6 hours while on heparin. Heparin was discontinued between 24 and 30 hours after tPA. Within 1 hour after discontinuation of heparin, apixaban or rivaroxaban was started orally at maintenance dose. All patients received chest compressions and epinephrine. Atropine was given to 19 patients.

2.4. Statistical analysis

Changes in PASP and RV/LV over time were evaluated using repeated-measures analysis of variance, with Bonferroni-corrected post hoc dependent-sample *t* tests. The pairwise analyses were repeated using a nonparametric approach (Wilcoxon signed rank test). Continuous variables are presented as mean \pm SD. $P < .05$ was considered statistically significant. Statistical analyses were performed with SPSS version 21 (IBM Corp, Armonk, NY).

3. Results

3.1. Patient characteristics

From February 2013 to December 2015, our group was consulted and treated 23 patients with PEA due to massive PE in the emergent setting of cardiopulmonary arrest and ongoing CPR. The patients' clinical characteristics are shown in Table 1. All patients had developed PEA during their arrest. Asystole developed in 9 patients after PEA (Fig. 2). There was no ventricular tachycardia or fibrillation. There were 4 patients who were on warfarin of whom 2 had therapeutic and 2 subtherapeutic international normalized ratio.

3.2. Clinical outcome

With administration of tPA, return of spontaneous circulation and hemodynamic stability (palpable pulse and systolic BP >100 mm Hg) was achieved following 2 to 15 minutes after administration of tPA in all but 1 patient. He died of irreversible shock 10 hours after admission. The time from initiation of CPR to administration of tPA was 6.5 ± 2.1 minutes. Sinus tachycardia was the rhythm that occurred after restoration of spontaneous circulation in all patients (Fig. 3). There was no in-hospital minor or major bleeding despite chest compression. Another patient developed permanent hypoxic encephalopathy due to prolonged CPR and late arrival, although spontaneous circulation had been restored. She arrived at the ED while receiving chest compressions by the paramedics (approximately 20 minutes of travel time and unclear duration of “downtime” before paramedics arrival) and received another 11 minutes of chest compressions in the ED. She died of multisystem organ failure 8 days after admission. Diagnosis of PE was made by point-of-care echocardiography. There was no recurrent venous thromboembolism in hospital or at follow-up. Indefinite anticoagulation was given to all surviving patients. The mean aPTT

Table 1
Clinical characteristics of patients

Variable	Patients, n = 23 (100%)
Men	9 (39%)
Age (y), mean ± SD	72 ± 5
Body mass index, mean ± SD	35 ± 3
Previous or concomitant disease	
Hypertension	15 (65%)
Diabetes mellitus	10 (43%)
Cardiovascular disease	7 (30%)
Hypercholesterolemia	13 (57%)
Pulmonary disease	14 (61%)
Renal disease	5 (22%)
Current smoker	10 (43%)
Unprovoked PE	16 (70%)
Estrogen/testosterone therapy	6 (26%)
Cancer	
Active	3 (13%)
History	5 (22%)
Known prothrombotic state	6 (26%)
Previous VTE	7 (30%)
Concomitant DVT	15 (65%)
D-Dimer elevation	23 (100%)
Troponin I elevation	23 (100%)
BNP elevation	23 (100%)
RV enlargement	23 (100%)
RV hypokinesia	23 (100%)

Hypercholesterolemia = total cholesterol greater than 200 mg/dL.
Abbreviations: BNP, brain natriuretic peptide; RV, right ventricle; VTE, venous thromboembolism.

after 6 hours was 55 ± 6 seconds and at 24 hours was 64 ± 8 seconds. Within 30 hours, 21 patients were extubated. Apixaban was given to 16 patients at maintenance dose of 5 mg orally twice daily and rivaroxaban to 5 patients at 20 mg orally daily. No loading dose was given. Additional aspirin at 81 mg daily was given to the 15 patients who had deep vein thrombosis. The changes in RV/LV ratio and PASP are shown in Table 2. Both parameters showed a decrease over time ($P < .001$). In addition, each of the pairwise comparisons over time was statistically significant ($P < .001$). The mean RV/LV was very high on admission and at 1.79 ± 0.27 (Fig. 4). One patient died of cancer 15 months after discharge. At a mean follow-up of 22 ± 3 months, 20 (87%) of the 23

patients were still alive. No bleeding occurred at 22 ± 3 months of follow-up. Although no formal quality-of-life instruments were uniformly used, all surviving patients reported a return to before event functional capacity without any restrictions which could be attributed to PE.

3.3. Limitations

Although patients were followed up in a prospective fashion after discharge from the hospital, this was a retrospective study as patients were identified in a retrospective fashion. There were no control groups, and no information is available on the outcome of patients with the same presentation who were seen by other providers in the same timeframe. Nonetheless, the result reflects an encouraging outcome with the suggested treatment protocol.

4. Discussion

The results indicate that systemic administration of 50 mg of tPA in 1 minute while CPR is ongoing is highly safe and effective in the treatment of PEA and cardiopulmonary collapse due to massive PE leading to restoration of spontaneous circulation within a short period.

In witnessed out-of-hospital arrest, PEA is an almost always fatal occurrence with only 4% of patients leaving the hospital alive [1]. It constitutes 20% of victims of cardiac arrest [1]. There is a paucity of data on the outcome of thrombolytic therapy in PEA due to confirmed PE. Most studies have reported on thrombolysis in undifferentiated PEA or in PEA due to suspected but not necessarily confirmed PE [2,3,9]. This article is therefore one of the few which reports on PEA due to massive PE with 100% confirmation. Favorable results have been noted with thrombolysis in patients with a high suspicion for PE [10–14]. The American Heart Association gives a grade IIa for administration of thrombolytic therapy during cardiac arrest due to PE [7]. In 1995, Jerjes-Sanchez et al [10] randomized 8 patients with massive PE and shock (but no PEA) to IV streptokinase plus heparin vs heparin alone. All 4 patients in the streptokinase group survived, whereas all 4 patients in the control group died ($P = .02$) [10]. In a retrospective review of 21 patients with massive PE and shock or cardiac arrest, tPA was administered at 0.6 mg/kg (maximum dose, 50 mg) over 15 minutes, followed by heparin

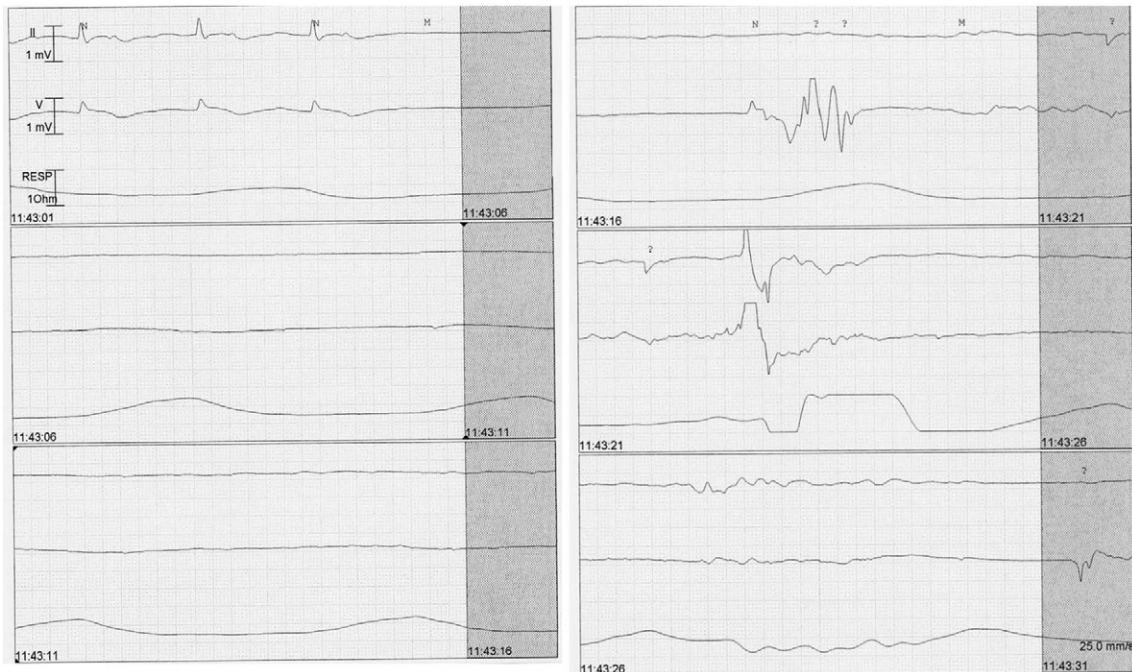

Fig. 2. Pulseless electrical activity degenerating into asystole.

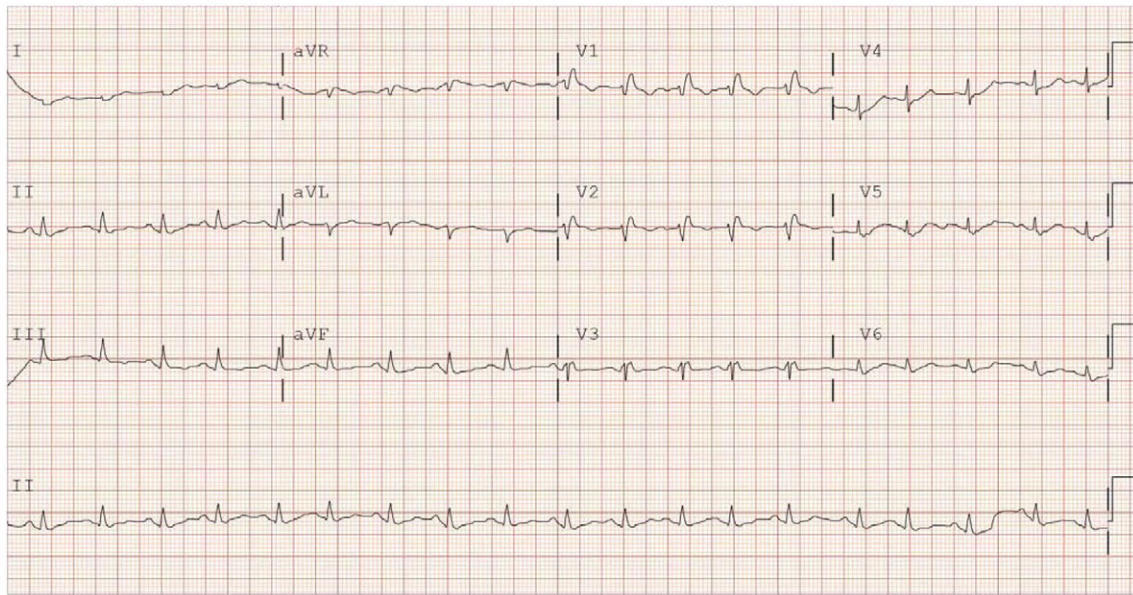


Fig. 3. Sinus tachycardia with suggestive features of PE shortly after thrombolytic therapy in the same patient of Fig. 2.

[11]. The mortality rate was 23.8%. Significant improvement in hemodynamic parameters and oxygenation saturation was noted at 2 hours. There was no major bleeding and minor bleeding that occurred in 23% of the patients [11]. A review of 9 reports involving 67 patients who were treated with thrombolytic agents during cardiac arrest for suspected PE demonstrated an overall survival rate of 75% [12]. Another retrospective study found that tPA therapy was associated with significant increases in the rates of return of spontaneous circulation, 24-hour survival, and survival to discharge [13]. In a meta-analysis of CPR with and without the administration of thrombolytic agents, the authors concluded that thrombolytics increased the rate of return of spontaneous circulation, survival to discharge, and long-term neurologic function in patients with PE as a cause of cardiac arrest [14].

There have been conflicting results on the outcome of thrombolytic therapy in undifferentiated PEA [2,3,9]. Hospital mortality was similar in 99 patients who had received thrombolysis vs 1087 patients who did not in undifferentiated cardiac arrest [9]. In a prospective, randomized, placebo-controlled trial (TROICA) involving 1050 patients with witnessed out-of-hospital cardiac arrest attributed to a cardiac etiology who were randomized to a weight adjusted tenecteplase treatment vs heparin, no difference in survival was noted [3]. Intracerebral hemorrhage developed in 2.7% with tenecteplase vs 0.4% with placebo ($P < .05$) [3].

A Canadian randomized controlled trial comparing thrombolysis (100 mg of tPA given in 15 minutes) with placebo in 233 patients who had PEA and cardiac arrest found no beneficial effect of thrombolysis. All but 1 of the patients (who was in the thrombolysis group) died [2]. In this study, only 2.4% of the patients had autopsy-confirmed PE. No uniform parenteral anticoagulation regimen was used, and tPA was

given very late in the course of CPR [2]. The median time from patient collapse to commencement of tPA infusion was 35 minutes which is over 5 times more delayed than that seen in our patients and 15 times longer for tPA administration than our protocol.

Low-dose systemic tPA at 50 mg has been shown to be very safe and effective in the treatment of massive and submassive PE [8,15]. The said dose has not led to any intracerebral hemorrhage or major bleeding when concomitant parenteral anticoagulation dose is lowered. In fact, risk of bleeding with low dose tPA is similar or lower than parenteral anticoagulation [8]. In the MOPETT trial, 121 patients with submassive or moderate PE were randomized to receive low or “safe dose” thrombolysis plus a modified dose of parenteral anticoagulation vs standard parenteral anticoagulation [8]. The “safe dose” thrombolysis regimen consisted of 50 mg of tPA in 2 hours (10 mg as IV bolus in 1 minute followed by 40 mg infusion in 2 hours). The same protocol was successfully used in patients with massive PE and shock with excellent results [15].

The current study demonstrates that 50 mg of tPA can be safely administered in 1 minute. Despite chest compressions and other invasive maneuvers during CPR, no internal or external bleeding occurred. The reduced dose of heparin given after CPR, its limitation to 30 hours,

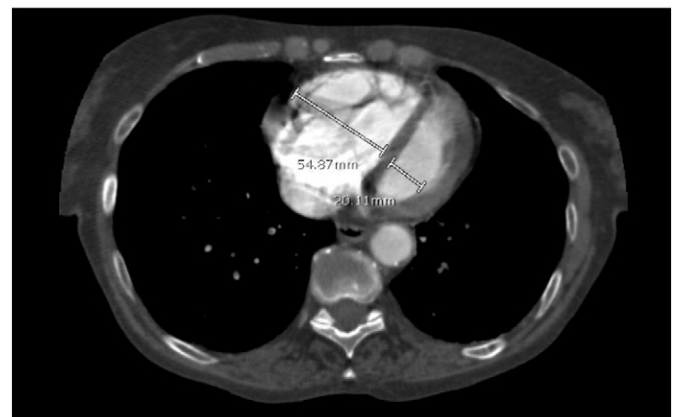


Fig. 4. Very high right/left ventricular ratio on a representative CT pulmonary angiogram at the ventricular level. Note the ratio is more than 2.7.

Table 2
Changes in echocardiographic parameters

Measurement period ^a	PASP (mm Hg)	RV/LV
Admission	58.10 ± 7.99	1.79 ± 0.27
Within 48 h	40.25 ± 4.33	1.16 ± 0.13
Last follow-up (22 ± 3 mo)	32.40 ± 4.67	0.93 ± 0.16

Data are expressed as mean ± SD.

^a Tests of trends showed statistically significant decreases over time in both parameters. All pairwise comparisons over time were also significant ($P < .001$).

and subsequent use of the maintenance dose of a new oral anticoagulant were potential contributing factors to no bleeding. However, given absence of a control group, such interpretation should be made with caution. All studies with new oral anticoagulants in venous thromboembolism have excluded patients who had received thrombolysis. It therefore stands to reason that, in those who do receive thrombolysis, the loading dose may be eliminated. This approach is our current practice. We also gave low-dose aspirin to patients with DVT. We have noted a reduction in postthrombotic syndrome in patients receiving aspirin [16]. The fact that 20 patients (87%) survived to 22 months after discharge is very encouraging. This figure is higher than many previous studies for several reasons: (1) PE was the cause of PEA in 100% of our patients. In most studies with lower success rate, PEA was of an undifferentiated etiology or was presumed to be present and not necessarily confirmed. (2) The administration of tPA was relatively early in the course of CPR. (3) It was given rapidly in only 1 minute. Our results are in keeping with the recommendations of a comprehensive literature review which concluded that unstable or arresting patients experiencing massive PE will likely benefit from thrombolytic therapy [17]. The authors recommended a similar 50 mg dose of tPA as initial bolus followed by a second 50 mg if the first dose is unsuccessful [17]. We do not believe that the second dose is necessary. Larger studies are required to evaluate the efficacy of our protocol in the setting of PEA and CPR due to massive PE.

5. Conclusions

We conclude that administration of 50 mg of tPA in 1 minute in patients with PEA due to confirmed PE is highly safe and effective leading to restoration of spontaneous circulation in the majority of such patients.

Supplementary data to this article can be found online at <http://dx.doi.org/10.1016/j.ajem.2016.06.094>.

References

- [1] Stueven HA, Aufderheide T, Waite EM, Mateer JR. Electromechanical dissociation: six years prehospital experience. *Resuscitation* 1989;17:173–82.
- [2] Abu-Laban RB, Christenson JM, Innes GD, et al. Tissue plasminogen activator in cardiac arrest with pulseless electrical activity. *N Engl J Med* 2002;346:1522–8.
- [3] Bottiger BW, Arntz HR, Chamberlain DA, et al. Thrombolysis during resuscitation for out-of-hospital cardiac arrest. *N Engl J Med* 2008;359:2651–62.
- [4] Hess EP, Campbell RL, White RD. Epidemiology, trends, and outcome of out-of-hospital cardiac arrest of non-cardiac origin. *Resuscitation* 2007;72:200–6.
- [5] Deasy C, Bray JE, Smith K, Harriss LR, Bernard SA, Cameron P. Out-of-hospital cardiac arrests in young adults in Melbourne, Australia—adding coronial data to a cardiac arrest registry. *Resuscitation* 2011;82:1302–6.
- [6] Hoek TL, Morrison LJ, Shuster M, et al. Part 12: cardiac arrest in special situations 2010 American Heart Association guidelines for cardiopulmonary resuscitation and emergency cardiovascular care. *Circulation* 2010;122:S829–61.
- [7] Neumar RW, Shuster M, Callaway CW, et al. Part 1: executive summary 2015 American Heart Association guidelines update for cardiopulmonary resuscitation and emergency cardiovascular care. *Circulation* 2015;132:S315–67.
- [8] Sharifi M, Bay C, Skrocki L, Rahimi F, Mehdipour M. Moderate pulmonary embolism treated with thrombolysis (from the “MOPETT” trial). *Am J Cardiol* 2013;111:273–7.
- [9] Stadlbauer KH, Krismer AC, Arntz HR, et al. Effects of thrombolysis during out-of-hospital cardiopulmonary resuscitation. *Am J Cardiol* 2006;97:305–8.
- [10] Jerjes-Sanchez C, Ramirez-Rivera A, de Lourdes Garcia M, et al. Streptokinase and heparin versus heparin alone in massive pulmonary embolism: a randomized controlled trial. *J Thromb Thrombolysis* 1995;2:227–9.
- [11] Le Conte P, Huchet L, Trewick D, et al. Efficacy of alteplase thrombolysis for ED treatment of pulmonary embolism with shock. *Am J Emerg Med* 2003;21:438–40.
- [12] Newman DH, Greenwald I, Callaway CW. Cardiac arrest and the role of thrombolytic agents. *Ann Emerg Med* 2000;35:472–80.
- [13] Lederer W, Lichtenberger C, Pechlaner C, Kroesen G, Baubin M. Recombinant tissue plasminogen activator during cardiopulmonary resuscitation in 108 patients with out-of-hospital cardiac arrest. *Resuscitation* 2001;50:71–6.
- [14] Li X, Fu QL, Jing XL, et al. A meta-analysis of cardiopulmonary resuscitation with and without the administration of thrombolytic agents. *Resuscitation* 2006;70:31–6.
- [15] Sharifi M, Vajo Z, Freeman W, Bay C, Sharifi M, Schwartz F. Transforming and simplifying the treatment of pulmonary embolism: “safe dose” thrombolysis plus new oral anticoagulants. *Lung* 2015;193:369–74.
- [16] Sharifi M, Bay C, Mehdipour M, Sharifi J, for the TORPEDO investigators. Thrombus Obliteration by Rapid Percutaneous Endovenous Intervention in Deep Venous Occlusion (TORPEDO) trial: midterm results. *J Endovasc Ther* 2012;19:273–80.
- [17] Logan JK, Pantle H, Huiras P, Bessman E, Bright L. Evidence-based diagnosis and thrombolytic treatment of cardiac arrest or periarrest due to suspected pulmonary embolism. *Am J Emerg Med* 2014;32:789–96.